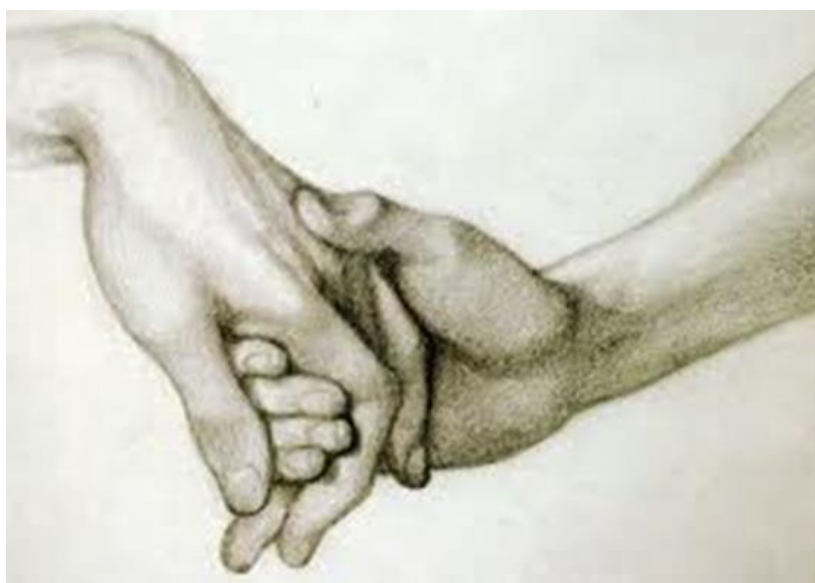

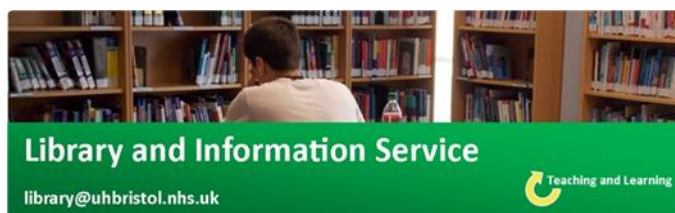Hand Rehabilitation

Evidence Update



December 2017
(Bimonthly)

Respecting everyone
Embracing change
Recognising success
Working together
Our hospitals.



Training Calendar 2017/18

All sessions are one hour

December (12.00-13.00)

7 th (Thu)	Statistics
14 th (Thu)	Literature Searching
20 th (Wed)	Critical Appraisal

January (13.00-14.00)

4 th (Thu)	Statistics
8 th (Mon)	Literature Searching
18 th (Thu)	Critical Appraisal
24 th (Wed)	Statistics

Your Outreach Librarian – **Helen Pullen**

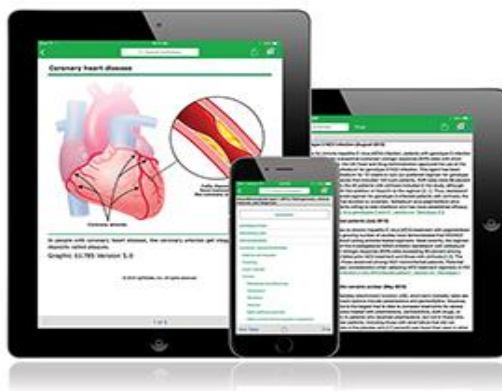Whatever your information needs, the library is here to help. Just email us at library@uhbristol.nhs.uk

Outreach: Your Outreach Librarian can help facilitate evidence-based practice for all in the team, as well as assisting with academic study and research. We also offer one-to-one or small group training in **literature searching, critical appraisal and medical statistics**. Get in touch: library@uhbristol.nhs.uk

Literature searching: We provide a literature searching service for any library member. For those embarking on their own research it is advisable to book some time with one of the librarians for a one-to-one session where we can guide you through the process of creating a well-focused literature research. Please email requests to library@uhbristol.nhs.uk



**UpToDate® is now available as a
Mobile App, free for all UHBristol staff**



Interested in staying up to date?

**Sign up at the Library, or email:
library@uhbristol.nhs.uk**

University Hospitals Bristol 
NHS Foundation Trust

Latest Evidence

NICE National Institute for
Health and Care Excellence

Searched but nothing relevant to add



[Vocational rehabilitation for enhancing return-to-work in workers with traumatic upper limb injuries](#)

Wen-Hsuan Hou , Ching-Chi Chi , Heng-Lien Lo , Yun-Yun Chou , Ken N Kuo and Hung-Yi Chuang

Online Publication Date: December 2017

[Rehabilitation following surgery for flexor tendon injuries of the hand](#)

Susan E Peters , Bhavana Jha and Mark Ross

Online Publication Date: January 2017

UpToDate[®]

OpenAthens login required. Register here: <https://openathens.nice.org.uk/>

Searched but nothing relevant to add

Journal Tables of Contents

Click on the **journal title (+ Ctrl)** for the most recent tables of contents.

If you would like any of the papers in full text then please email the library:

library@uhbristol.nhs.uk

Journal of Hand Surgery (British and European)

Volume 42, Issue 9, November 2017

Journal of Hand Surgery (America)

Volume 42, Issue 12, December 2017

Journal of Hand Therapy

Volume 30, Issue 4, Oct-Dec 2017

Database Articles

Below is a selection of articles that were recently added to the healthcare databases. If you would like any of the following articles in full text, or if you would like a more focused search on your own topic, then get in touch: library@uhbristol.nhs.uk

Wrist and Finger fractures (distal radius/scaphoid)

1. Classification systems for distal radius fractures: Does the reliability improve using additional computed tomography?

Author(s): KLEINLUGTENBELT, Ydo V.; GROEN, Sylvester R.; HAM, S. John; KLOEN, Peter; HAVERLAG, Robert; SIMONS, Maarten P.; SCHOLTES, Vanessa A. B.; BHANDARI, Mohit; GOSLINGS, J. Carel; POOLMAN, Rudolf W.

Source: Acta Orthopaedica; Dec 2017; vol. 88 (no. 6); p. 681-687

Publication Date: Dec 2017

Publication Type(s): Academic Journal

Available at [Acta orthopaedica](#) - from Europe PubMed Central - Open Access

Available at [Acta orthopaedica](#) - from EBSCO (CINAHL with Full Text)

Available at [Acta orthopaedica](#) - from EBSCO (MEDLINE Complete)

Abstract:Background and purpose -- The reliability of conventional radiography when classifying distal radius fractures (DRF) is fair to moderate. We investigated whether reliability increases when additional computed tomography scans (CT) are used. Patients and methods -- In this prospective study, we performed pre- and postreduction posterior-anterior and lateral radiographs of 51 patients presenting with a displaced DRF. The case was included when there was a (questionable) indication for surgical treatment and an additional CT was conducted within 5 days. 4 observers assessed the cases using the Frykman, Fernández, Universal, and AO classification systems. The first 2 assessments were performed using conventional radiography alone; the following 2 assessments were performed with an additional CT. We used the intraclass correlation coefficient (ICC) to evaluate reliability. The CT was used as a reference standard to determine the accuracy. Results -- The intraobserver ICC for conventional radiography alone versus radiography and an additional CT was: Frykman 0.57 vs. 0.51; Fernández 0.53 vs. 0.66; Universal 0.57 vs. 0.64; AO 0.59 vs. 0.71. The interobserver ICC was: Frykman: 0.45 vs. 0.28; Fernández: 0.38 vs. 0.44; Universal: 0.32 vs. 0.43; AO: 0.46 vs. 0.40. Interpretation -- The intraobserver reliability of the classification systems was fair but improved when an additional CT was used, except for the Frykman classification. The interobserver reliability ranged from poor to fair and did not improve when using an additional CT. Additional CT scanning has implications for the accuracy of scoring the fracture types, especially for simple fracture types.

Database: CINAHL

2. Validity and responsiveness of the Simple Test for Evaluating Hand Function.

Author(s): Irie, Keisuke; Iseki, Hirokatsu; Okamoto, Satomi; Nishimura, Seiji; Kobe, Akio; Kagechika, Kenji

Source: Hand Therapy; Dec 2017; vol. 22 (no. 4); p. 133-140

Publication Date: Dec 2017

Publication Type(s): Academic Journal

Abstract:Introduction Despite widespread use of the Simple Test for Evaluating Hand Function, we were unable to find studies to affirm the validity and responsiveness in patients with trauma and inflammatory diseases. The aim of this study was to demonstrate the criterion validity and responsiveness of the Simple Test for Evaluating Hand Function, a tool which is widely used in Japan. Methods Thirty patients between the ages of 20 and 82 years with distal radius fracture (n = 10), and cervical spondylosis myelopathy (n = 20) were included in this study. Concurrent validity was tested by examining the correlation between Simple Test for Evaluating Hand Function, the Purdue Pegboard Test, and the Disabilities of the Arm, Shoulder and Hand questionnaire. In addition, standardized response means were calculated to compare the responsiveness of the Simple Test for Evaluating Hand Function with Purdue Pegboard Test and Disabilities of the Arm, Shoulder and Hand. Results The correlation coefficient between Simple Test for Evaluating Hand Function and Purdue Pegboard Test was 0.70, and the correlation between Simple Test for Evaluating Hand Function and Disabilities of the Arm, Shoulder and Hand was -0.55 (p < 0.05). Standardized response mean shows that the Simple Test for Evaluating Hand Function (0.69) is more responsive than the Purdue Pegboard Test (0.53), and less responsive than Disabilities of the Arm, Shoulder and Hand (0.97). Conclusions The Simple Test for Evaluating Hand Function demonstrates concurrent validity and responsiveness as a performance based assessment of dexterity in patients with distal radius fracture and cervical spondylosis. We conclude that the Simple Test for Evaluating Hand Function could be used as a measure of dexterity or clinical change after therapy intervention. The Purdue Pegboard Test may be used for patients with an occupation that requires integrated fine motor skills and bimanual activity, whereas the Simple Test for Evaluating Hand Function may be more suitable for patients who use a variety of unilateral grips such as pinch and span. The Simple Test for Evaluating Hand Function and Disabilities of the Arm, Shoulder and Hand can complement each other when measuring someone's activity and participation level.

Database: CINAHL

3. Upper-limb motor and sensory function in patients with hip fracture: Comparison with community-dwelling older adults.

Author(s): Hiroyuki Hayashi; Daiki Nakashima; Hiroka Matsuoka; Midori Iwai; Shugo Nakamura; Ayumi Kubo; Naoki Tomiyama

Source: Journal of Back & Musculoskeletal Rehabilitation; Nov 2017; vol. 30 (no. 6); p. 1231-1236

Publication Date: Nov 2017

Publication Type(s): Academic Journal

Abstract:BACKGROUND: Upper-limb function is important in patients with hip fracture so they can perform activities of daily living and participate in leisure activities. Upper-limb function of these patients, however, has not been thoroughly investigated. OBJECTIVE: The aim of this study was to evaluate the upper-limb motor and sensory functions in patients with hip fracture by comparing these functions with those of community-dwelling older adults (control group). METHODS: We compared the results of motor and sensory function tests of upper-limb function - range of motion, strength, sensibility, finger dexterity, comprehensive hand function - between patients with hip fracture (n = 32) and the control group (n = 32). RESULTS: Patients with hip fracture had significantly reduced grip strength, pinch strength, finger dexterity, and comprehensive hand function compared with the control group. CONCLUSIONS: Most upper-limb functions are impaired in the patients with hip fracture. Thus, upper-limb function of patients with hip fracture should be considered during treatment.

Database: CINAHL

4. A Rare Complete Metacarpal Pseudoepiphysis in a Teenager With a Scaphoid Fracture.

Author(s): Geffen, Rachel B.; Colberg, Ricardo E.

Source: American Journal of Physical Medicine & Rehabilitation; Nov 2017; vol. 96 (no. 11)

Publication Date: Nov 2017

Publication Type(s): Academic Journal

Abstract: A 13-yr-old adolescent boy presented with wrist pain after falling off a scooter onto his outstretched hand. Radiographs revealed a nondisplaced hairline fracture of the scaphoid bone and an irregular radiolucent line in the proximalmetaphysis of the secondmetacarpal bone, consistent with an anomalous growth plate, or complete pseudoepiphysis. Complete pseudoepiphysis is a rare finding, with only a few cases reported. Learning about the common locations of growth plates and the radiographic differences between normal, injured, and anomalous growth plates can help decrease physician error and improve patient outcomes.

Database: CINAHL

5. Digital Tomography for Detection of Acute Occult Scaphoid Fractures.

Author(s): BARCIA, ANTHONY M.; LIANG ZHOU; COOK, JAY B.; LINDELL, KENNETH K.; GUMBOC, REY D.; DYKSTRA, AARON D.; LACHKY, ROBERT J.; SHAHA, STEVEN H.; TAYLOR, KENNETH F.; Zhou, Liang

Source: Orthopedics; Nov 2017; vol. 40 (no. 6)

Publication Date: Nov 2017

Publication Type(s): Academic Journal

PubMedID: 29116329

Abstract: Diagnosis of occult scaphoid fractures remains a challenge. Traditional management consisting of 2 weeks of immobilization and repeat radiographs results in unnecessary immobilization of many patients without fracture. Magnetic resonance imaging (MRI) is sensitive but expensive. Digital tomography (DT) is an imaging technique that provides fine-cut visualization with minimal radiation exposure and may be used when there is high clinical suspicion despite negative findings on initial radiographs. The authors compared the ability of DT vs MRI to detect acute occult scaphoid fractures. This was an institutional review board-approved, prospective series. Adults for which clinical suspicion for acute scaphoid fracture (presenting within 96 hours of trauma) and negative findings on initial radiographs existed were included. Both a wrist tomogram and MRI were obtained. Wrists were immobilized and reevaluated at 10 to 14 days with repeat radiographs as a control. Studies were interpreted by a radiologist in a blinded fashion. Forty consecutive extremities in 39 patients met the inclusion criteria. Six (15%) of the 40 scaphoids were determined to be fractured on repeat radiographs. Digital tomogram yielded positive findings in 4 of these. Magnetic resonance imaging yielded positive findings in 8 (20%) of the 40 extremities. Sensitivities were 67% and 100% for digital tomogram and MRI, respectively ($P=.0001$). The positive predictive value was 100% for DT and MRI. The authors found that DT detects more occult scaphoid fractures than initial standard radiographs but is less sensitive than MRI. This is the first study to compare DT with MRI. Digital tomography can be used to augment radiographs and may increase diagnostic efficiency, minimize unnecessary immobilization, and reduce health care costs. [Orthopedics. 2017; 40(6):e1092-e1095.]

Database: CINAHL

6. Fractures of the Scaphoid.

Author(s): Shymko, Michael

Source: Radiologic Technology; Nov 2017; vol. 89 (no. 2); p. 177-181

Publication Date: Nov 2017

Publication Type(s): Academic Journal

Abstract:The article discusses some important issues to put in mind when it comes to scaphoid fractures. Topics discussed include the five metacarpal bones that form the palm, an image that shows the anatomy of the left wrist showing common fracture regions of the scaphoid, and mechanisms of scaphoid injury.

Database: CINAHL

7. Repositioning the scapula with taping following distal radius fracture: Kinematic analysis using 3-dimensional motion system.

Author(s): Turgut, Elif; Ayhan, Cigdem; Baltaci, Gul

Source: Journal of Hand Therapy; Oct 2017; vol. 30 (no. 4); p. 477-482

Publication Date: Oct 2017

Publication Type(s): Academic Journal

Available at [Journal of hand therapy : official journal of the American Society of Hand Therapists](#) - from ProQuest (Hospital Premium Collection) - NHS Version

Abstract:Study Design Cross-sectional and controlled laboratory study using pretest-posttest design. Introduction Patients with distal radius fracture (DRfx) report proximal segment problems. Taping is commonly recommended because it provides improved posture and function. Purpose of the Study This study aimed to investigate the 3-dimensional scapular kinematics and the effect of taping on the kinematics in participants with DRfx. Methods Twenty participants with a unilateral history of DRfx and 20 healthy controls participated. Scapular kinematics was assessed using an electromagnetic system. Three separate strips of elastic taping were applied for participants with DRfx over the arm, scapula, and middle and lower trapezius muscles through the paravertebral muscles. Afterward, the scapular kinematics was reassessed in taped condition. Results When participants with DRfx and healthy controls compared, the scapula was more downwardly rotated at 120° of humerothoracic elevation (mean difference [MD], 9.06°) and at 120° (MD, 9.04°), 90° (MD, 5.6°) of humerothoracic lowering, more upwardly rotated at 30° of humerothoracic lowering (MD, 5.1°). Taping showed a significant effect on kinematics; specifically, the scapula was more externally rotated (38.9° untaped vs 31.1° taped) and posteriorly tilted (-9.2° untaped vs -4.8° taped) during humerothoracic elevation and lowering for participants with DRfx. Discussion Participants with DRfx showed different scapular kinematics and taping resulted in changes on tested kinematic parameters during humeral movements. Differences in scapular motion during elevation with taping showed a specific pattern. Conclusions Overall, taping maintained a position likely to produce optimal rotator cuff function during early rehabilitation of patients with DRfx. Level of Evidence N/A.

Database: CINAHL

8. Prescribed exercise programs may not be effective in reducing impairments and improving activity during upper limb fracture rehabilitation: a systematic review.

Author(s): Bruder, Andrea M; Shields, Nora; Dodd, Karen J; Taylor, Nicholas F

Source: Journal of Physiotherapy (Elsevier); Oct 2017; vol. 63 (no. 4); p. 205-220

Publication Date: Oct 2017

Publication Type(s): Academic Journal

Abstract: Question What is the effect of exercise on increasing participation and activity levels and reducing impairment in the rehabilitation of people with upper limb fractures? Design Systematic review of controlled trials. Participants Adults following an upper limb fracture. Intervention Any exercise therapy program, including trials where exercise was delivered to both groups provided that the groups received different amounts of exercise. Outcome measures Impairments of body structure and function, activity limitations and participation restrictions. Results Twenty-two trials were identified that evaluated 1299 participants with an upper limb fracture. There was insufficient evidence from 13 trials to support or refute the effectiveness of home exercise therapy compared with therapist-supervised exercise or therapy that included exercise following distal radius or proximal humeral fractures. There was insufficient evidence from three trials to support or refute the effectiveness of exercise therapy compared with advice/no exercise intervention following distal radius fracture. There was moderate evidence from five trials (one examining distal radius fracture, one radial head fracture, and three proximal humeral fracture) to support commencing exercise early and reducing immobilisation in improving activity during upper limb rehabilitation compared with delayed exercise and mobilisation. There was preliminary evidence from one trial that exercise to the non-injured arm during immobilisation might lead to short-term benefits on increasing grip strength and range of movement following distal radius fracture. Less than 40% of included trials reported adequate exercise program descriptions to allow replication according to the TIDieR checklist. Conclusion There is emerging evidence that current prescribed exercise regimens may not be effective in reducing impairments and improving activity following an upper limb fracture. Starting exercise early combined with a shorter immobilisation period is more effective than starting exercise after a longer immobilisation period. Registration CRD42016041818. [Bruder AM, Shields N, Dodd KJ, Taylor NF (2017) Prescribed exercise programs may not be effective in reducing impairments and improving activity during upper limb fracture rehabilitation: a systematic review. *Journal of Physiotherapy* 63: 205–220]

Database: CINAHL

Wrist and Finger fractures (distal radius/scaphoid)

1. Treatment of dorsal fracture-dislocation of the proximal interphalangeal joint using the Ligamentotaxor device: clinical and radiographic preliminary results.

Author(s): Kostoris, Francesco; Canton, Gianluca; Longo, Emiliano; Romano, Francesco; Murena, Luigi

Source: *Acta bio-medica : Atenei Parmensis*; Oct 2017; vol. 88 (no. 4)

Publication Date: Oct 2017

Publication Type(s): Journal Article

PubMedID: 29083359

Abstract: BACKGROUND AND AIM OF THE WORK Fracture-dislocations of the proximal interphalangeal joint are complex injuries, often difficult to treat. Several treatment options have been described. Among them dynamic external fixation proved to be a safe technique leading to good results in many authors experience. The principles of this treatment are to avoid edema, prevent stiffness and tendon adhesions, promote joint remodelling and facilitate rehabilitation. The Ligamentotaxor® device is a simple and reproducible dynamic external fixation system that has been used in recent years to treat proximal interphalangeal joint fracture-dislocations, with favourable results. The aim of the present study is to evaluate our preliminary results with the Ligamentotaxor® device for treatment of these complex lesions. METHODS Four patients between December 2015 and January 2017 were treated at our institution with the Ligamentotaxor® device. Clinical and radiographic results were evaluated at mean 6 months follow-up. RESULTS Clinical results were

meanly good and appeared to be comparable to most recent literature. Mean range of motion was 60,5°, mean extension lag 18,5°. Mean QuickDASH and Michigan Hand Questionnaire scored 21.6 and 72 respectively. Radiographic evaluation showed fracture healing in all cases. No relevant complications were noted. **CONCLUSION** The Ligamentotaxor® device is simple to implant, provides good stability and allows an immediate gentle active movement. According to present work the preliminary results are encouraging.

Database: Medline

2. Congenital extensor tendon dislocation causing pseudotriggering of the little finger.

Author(s): Çırpar, Meriç; Dağlar, Bülent; Oktaş, Birhan

Source: Acta orthopaedica et traumatologica turcica; Oct 2017; vol. 51 (no. 5); p. 429-431

Publication Date: Oct 2017

Publication Type(s): Journal Article

PubMedID: 28454779

Available at [Acta Orthopaedica et Traumatologica Turcica](#) - from EBSCO (MEDLINE Complete)

Abstract: The main complaints in extensor tendon dislocations are pain, swelling, sense of discomfort, snapping and difficulty in writing and forceful flexion. However, congenital extensor tendon subluxations may present with triggering of the fingers due to tendon dislocations. Unnecessary A1 pulley release may be performed for pseudotriggering with unsuccessful results. Here, we report an unusual case of congenital extensor tendon subluxation of multiple digits with triggering of the left little finger and aim to attract notice to pseudotriggering of the digits due to tendon dislocations. An extensor hood reconstruction performed by an extensor digitorum communis tendon slip which is passed beneath the deep intermetacarpal ligament is a successful choice of treatment for these patients.

Database: Medline

Dupuytren's (fasciectomy)

1. Dupuytren's Contracture: Current Treatment Methods.

Author(s): Feldman, Guy; Rozen, Nimrod; Rubin, Guy

Source: The Israel Medical Association journal : IMAJ; Oct 2017; vol. 19 (no. 10); p. 648-650

Publication Date: Oct 2017

Publication Type(s): Journal Article Review

PubMedID: 29103246

Available at [The Israel Medical Association journal : IMAJ](#) - from EBSCO (MEDLINE Complete)

Abstract: **BACKGROUND** Dupuytren's disease is a common benign fibromatosis of the palmar and digital fascia. The exact pathophysiology and epidemiology of this condition have not been entirely identified. Pathologic fibrous bands cause a flexion contracture of the metacarpal phalangeal joints and proximal interphalangeal joint. Treatment includes fasciectomy, needle fasciotomy, and enzymatic fasciectomy.

Database: Medline

2. Complications after treating Dupuytren's disease. A systematic literature review.

Author(s): Krefter, C; Marks, M; Hensler, S; Herren, D B; Calcagni, M

Source: Hand surgery & rehabilitation; Oct 2017; vol. 36 (no. 5); p. 322-329

Publication Date: Oct 2017

Publication Type(s): Journal Article

PubMedID: 28917432

Abstract:The objective of this study was to review the incidence of complications associated with different treatment options for patients with Dupuytren's disease. In a systematic literature review, the PubMed, EMBASE, Cochrane and Scopus databases were searched for clinical studies reporting complications after collagenase treatment, percutaneous needle fasciotomy (PNF), fasciectomy and dermofasciectomy. The incidence of complications was extracted from each study and stratified by procedure. From a total of 2251 references, 113 studies were analyzed and included with complication incidences varying from 0% to 100%. The highest number of nerve and vessel lesions were reported after fasciectomy, whereas the highest rate of edema was after collagenase injection. Accidental skin tears were mostly associated with collagenase and PNF treatment. Pooled complication incidences were 17.4% (95% CI: 11.7-23.1) for fasciectomy, 78.0% (95% CI: 59.6-96.4) for collagenase treatment, 18.9% (95% CI: -5.5-43.3) for PNF and 11.6% (95% CI: 0.0-23.2) for dermofasciectomy. Due to inconsistencies in reporting complications as well as the lack of a standardized definition, the literature does not provide evidence in favor of a specific procedure for Dupuytren's disease. A standardized definition of complications is required to improve the comparability of published results.

Database: Medline

DeQuervain & tenosynovitis

1. Real-life effectiveness of spa therapy in rheumatic and musculoskeletal diseases: a retrospective study of 819 patients.

Author(s): Karagülle, Mine; Kardeş, Sinan; Karagülle, Müfit Zeki

Source: International journal of biometeorology; Nov 2017; vol. 61 (no. 11); p. 1945-1956

Publication Date: Nov 2017

Publication Type(s): Journal Article

PubMedID: 28560466

Abstract:The objective of this study is to determine the use and efficacy of spa therapy in patients with a wide spectrum of rheumatic and musculoskeletal diseases under real-life clinical practice circumstances. In this retrospective observational study at the Medical Ecology and Hydroclimatology Department of Istanbul Faculty of Medicine, the records of all adult patients with rheumatic and musculoskeletal diseases who were prescribed a spa therapy in various health resorts in Turkey between 2002 and 2012 were analyzed. Patients sojourned to and stayed at a health resort and followed a usual 2-week course of spa therapy. The patients were examined within a week before and after the spa therapy at the department by the physicians and outcome measures were pain intensity (visual analog scale, VAS), patient's general evaluation (VAS), physician's general evaluation (VAS), Health Assessment Questionnaire (HAQ), Lequesne's Functional Index (LFI), Western Ontario and McMaster Universities Index (WOMAC), Waddell Index (WI), Neck Pain and Disability Scale (NPDS), Shoulder Disability Questionnaire (SDQ), Fibromyalgia Impact Questionnaire (FIQ), and Beck's Depression Inventory (BDI). In total, 819 patients were included in the analysis. The diagnoses were 536 osteoarthritis; 115 fibromyalgia; 50 lumbar disc herniation; 34 cervical disc

herniation; 23 nonspecific low back pain; 22 ankylosing spondylitis; 16 rheumatoid arthritis; 9 rotator cuff tendinitis; and 14 other conditions/diseases including scoliosis, stenosing flexor tenosynovitis, congenital hip dislocation in adult, Behçet's disease, de Quervain tendinopathy, psoriatic arthritis, osteoporosis, fracture rehabilitation, and diffuse idiopathic skeletal hyperostosis. Statistically significant decrease in pain scores was found in all patients except hip osteoarthritis ($p = 0.063$) and rheumatoid arthritis ($p = 0.134$) subgroups; and statistically significant improvement in function in all patients except hip osteoarthritis ($p = 0.068$), rheumatoid arthritis ($p = 0.111$), and rotator cuff tendinitis ($p = 0.078$) subgroups. In daily clinical practice, spa therapy is prescribed and practiced mainly for osteoarthritis, then fibromyalgia, lumbar/cervical disc herniation, and nonspecific low back pain; and less for ankylosing spondylitis, rheumatoid arthritis, and rotator cuff tendinitis. The study results suggest that real-life spa therapy may be effective in a variety of rheumatic and musculoskeletal diseases by improving pain and function.

Database: Medline

Mallet Finger/Thumb Deformity

1. Design of a wearable and shape-memory fibriform sensor for the detection of multimodal deformation.

Author(s): Li, Li; Shi, Peipei; Hua, Li; An, Jianing; Gong, Yujiao; Chen, Ruyi; Yu, Chenyang; Hua, Weiwei; Xiu, Fei; Zhou, Jinyuan; Gao, Guangfa; Jin, Zhong; Sun, Gengzhi; Huang, Wei

Source: Nanoscale; Dec 2017

Publication Date: Dec 2017

Publication Type(s): Journal Article

PubMedID: 29211073

Abstract: A wearable and shape-memory strain sensor with a coaxial configuration is designed, comprising a thermoplastic polyurethane fiber as the core support, well-aligned and interconnected carbon nanotubes (CNTs) as conductive filaments, and polypyrrole (PPy) coating as the cladding layer. In this design, the stress relaxation between CNTs is well confined by the outer PPy cladding layer, which endows the fibriform sensor with good reliability and repeatability. The microcracks generated when the coaxial fiber is under strain guarantee the superior sensitivity of this fibriform sensor with a gauge factor of 12 at 0.1% strain, a wide detectable range (from 0.1% to 50% tensile strain), and the ability to detect multimodal deformation (tension, bending, and torsion) and human motions (finger bending, breathing, and phonation). In addition, due to its shape-memory characteristic, the sensing performance of the fibriform sensor is well retained after its shape recovers from 50% deformation and the fabric woven from the shape-memory coaxial fibers can be worn on the elbow joints in a reversible manner (original-enlarged-recovered) and fitted tightly. Thus, this sensor shows promising applications in wearable electronics.

Database: Medline

2. Surgical and Nonsurgical Management of Mallet Finger: A Systematic Review.

Author(s): Lin, James S; Samora, Julie Balch

Source: The Journal of hand surgery; Nov 2017

Publication Date: Nov 2017

Publication Type(s): Journal Article

PubMedID: 29174096

Abstract: PURPOSE The current literature describes multiple surgical and nonsurgical techniques for the management of mallet finger injuries, and there is no consensus on the indications for surgical treatment. The objective of this study was to determine, through a literature review, if any conclusions can be drawn concerning the indications for surgery in mallet finger injuries; the treatment outcomes of surgical versus nonsurgical management; the most effective methods of surgical and nonsurgical treatment; and the most common treatment complications of mallet finger injuries. METHODSA systematic review of multiple databases was performed. English language clinical studies evaluating therapeutic interventions for mallet fingers that reported objective, standardized outcome measures were included. Basic science studies, cadaveric studies, conference abstracts, level V evidence studies, studies lacking statistical data, and tendinous injuries other than mallet fingers were excluded. Salvage procedures and studies evaluating exclusively chronic lesions were also excluded. RESULTS Forty-four studies that reported clinical outcomes for the treatment of mallet finger injuries, 22 evaluating surgical treatments and 17 studies investigating nonsurgical treatments were included. The average distal interphalangeal joint extensor lag was 5.7° after surgical treatment and 7.6° after nonsurgical treatment. Complication rates of surgical and nonsurgical interventions were comparable (14.5% and 12.8%, respectively). Five studies directly compared the outcomes of surgical with nonsurgical management, with mixed results and recommendations. CONCLUSIONS Both surgical and nonsurgical treatments of mallet finger injuries lead to excellent clinical outcomes. Insufficient evidence is available to determine when surgical intervention is indicated. Based on our literature review, it appears that these treatments are equivalent and should be individualized to the patient. TYPE OF STUDY/LEVEL OF EVIDENCE Therapeutic IV.

Database: Medline

3. Mallet Finger in a Toddler: A Rare But Easily Missed Injury.

Author(s): Forward, Karen E; Yazdani, Arjang; Lim, Rodrick

Source: Pediatric emergency care; Oct 2017; vol. 33 (no. 10); p. e103

Publication Date: Oct 2017

Publication Type(s): Journal Article

PubMedID: 28968312

Abstract: A mallet finger is a flexion deformity of a finger at the distal interphalangeal joint due to an injury of the extensor mechanism at the base of the distal phalanx. Most common in middle-aged men, injuries in the pediatric population are less common and rare in toddlers. We describe a case of missed mallet finger and its subsequent treatment in a female toddler.

Database: Medline

Flexor and Tendon Injuries

1. Distal Biceps Tendon Injuries: Treatment of Partial and Complete Tears.

Author(s): Wylie, James D.; Wolf, Megan R.; DiVenere, Jessica; Mazzocca, Augustus D.

Source: Operative Techniques in Sports Medicine; Dec 2017; vol. 25 (no. 4); p. 304-309

Publication Date: Dec 2017

Publication Type(s): Periodical

Abstract: Distal biceps ruptures predominantly affect males in their third to fifth decade of life who are involved in heavy lifting or manual labor activities. This includes athletes from those in the

professional ranks to weekend warriors. They commonly describe a tearing event with the elbow in flexion and undergoing an eccentric load. The hook test is highly sensitive and specific in diagnosis. In the setting of partial-thickness tears, the hook test can be negative but can elicit pain. Magnetic resonance imaging is the imaging modality of choice to determine partial vs full-thickness tears and the degree of proximal migration of the tendon stump. Operative intervention is recommended for most athletes and people in need of elbow flexion and supination strength and endurance. Operative repair techniques have improved and now allow early range of motion and strengthening for return of patients to their sports or activities of choice with good clinical outcomes reported using multiple techniques. The authors preferred technique is the use of a suture button and interference screw construct that has been validated in both biomechanical testing and clinical outcomes studies.

Database: CINAHL



[Dispelling the nice or naughty myth: retrospective observational study of Santa Claus \(Park, J.J, Kennedy, B. G.T, et al , BMJ 2016; 355, 6355\)](#)

OBJECTIVES To determine which factors influence whether Santa Claus will visit children in hospital on Christmas Day.

DESIGN Retrospective observational study.

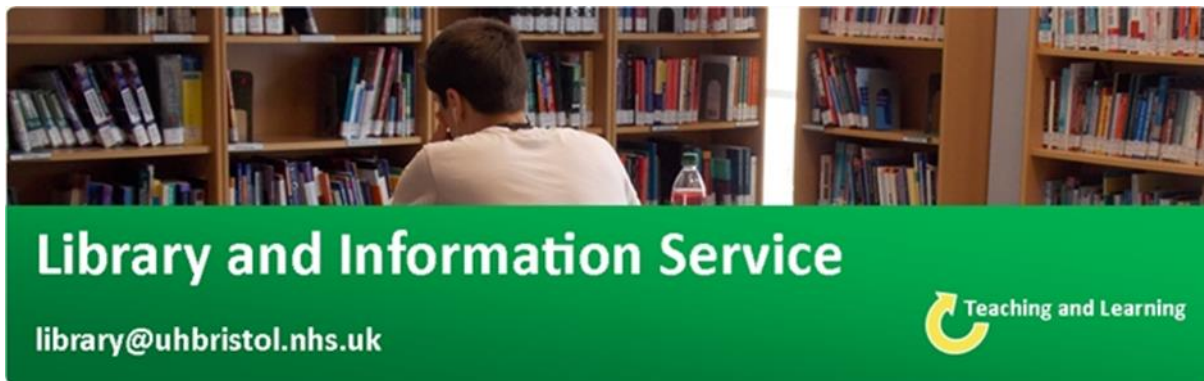
SETTING Paediatric wards in England, Northern Ireland, Scotland, and Wales.

PARTICIPANTS 186 members of staff who worked on the paediatric wards (n=186) during Christmas 2015.

MAIN OUTCOME MEASURES Presence or absence of Santa Claus on the paediatric ward during Christmas 2015. This was correlated with rates of absenteeism from primary school, conviction rates in young people (aged 10-17 years), distance from hospital to North Pole (closest city or town to the hospital in kilometres, as the reindeer flies), and contextual socioeconomic deprivation (index of multiple deprivation).

RESULTS Santa Claus visited most of the paediatric wards in all four countries: 89% in England, 100% in Northern Ireland, 93% in Scotland, and 92% in Wales. The odds of him not visiting, however, were significantly higher for paediatric wards in areas of higher socioeconomic deprivation in England (odds ratio 1.31 (95% confidence interval 1.04 to 1.71) in England, 1.23 (1.00 to 1.54) in the UK). In contrast, there was no correlation with school absenteeism, conviction rates, or distance to the North Pole.

CONCLUSION The results of this study dispel the traditional belief that Santa Claus rewards children based on how nice or naughty they have been in the previous year. Santa Claus is less likely to visit children in hospitals in the most deprived areas. Potential solutions include a review of Santa's contract or employment of local Santas in poorly represented regions.



Library Opening Times

Staffed hours: 08.00-17.00, Monday to Friday

Swipe-card access: 07.00-23.00, seven days a week

Level Five, Education and Research Centre
University Hospitals Bristol

Contact your Outreach Librarian:

Helen Pullen

library@uhbristol.nhs.uk