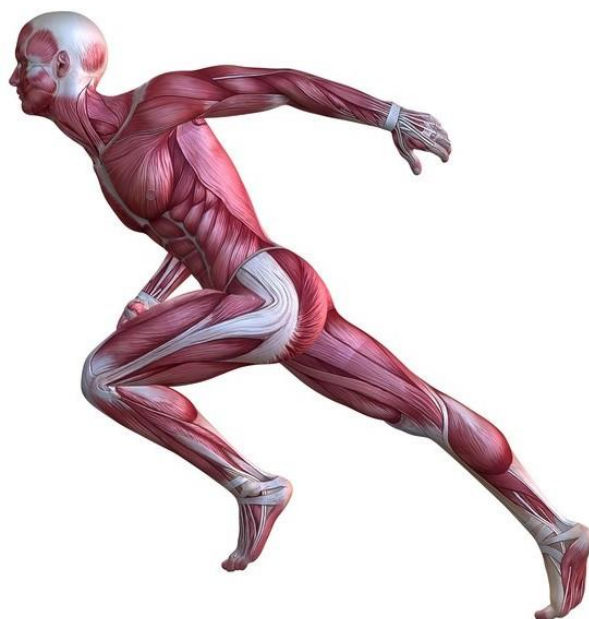

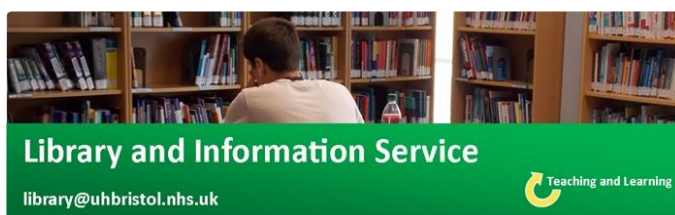# Musculoskeletal Soft Tissue Clinic

## Current Awareness Newsletter



**June 2017 (Quarterly)**

Respecting everyone  
Embracing change  
Recognising success  
Working together  
**Our hospitals.**



**Library and Information Service**

[library@uhbristol.nhs.uk](mailto:library@uhbristol.nhs.uk)



# Training Sessions 2017

*All sessions are one hour*

## July (13.00-14.00)

3rd (Mon) Interpreting Statistics  
12th (Wed) Critical Appraisal  
21st (Fri) Literature Searching  
26th (Wed) Interpreting Statistics

## August (12.00-13.00)

4th (Fri) Critical Appraisal  
9th (Wed) Literature Searching  
15th (Tues) Interpreting Statistics  
24th (Thurs) Critical Appraisal



## Your Local Librarian – Jo Hooper


Whatever your information needs, the library is here to help. As your outreach librarian I offer **literature searching services** as well as training and guidance in **searching the evidence** and **critical appraisal** – just email me at [library@uhbristol.nhs.uk](mailto:library@uhbristol.nhs.uk)

**OUTREACH:** Your Outreach Librarian can help facilitate evidence-based practise, as well as assisting with academic study and research. We can help with **literature searching, obtaining journal articles and books**, and setting up individual **current awareness alerts**. We also offer one-to-one or small group training in **literature searching, accessing electronic journals, and critical appraisal**. Get in touch: [library@uhbristol.nhs.uk](mailto:library@uhbristol.nhs.uk)

**LITERATURE SEARCHING:** We provide a literature searching service for any library member. For those embarking on their own research it is advisable to book some time with one of the librarians for a one-to-one session where we can guide you through the process of creating a well-focused literature research and introduce you to the health databases access via NHS Evidence. Please email requests to [library@uhbristol.nhs.uk](mailto:library@uhbristol.nhs.uk)

## Contents

Training Sessions 2017.....	2
.....	2
Your Local Librarian.....	2
<b>NICE</b> National Institute for Health and Care Excellence .....	5
 .....	5
 .....	6
<b>Current Awareness Database Articles related to Musculoskeletal Soft Tissue .....</b>	<b>6</b>
Acute soft tissue injuries .....	6
Musculoskeletal.....	10
Sports Injuries.....	14
<b>Journal Tables of Contents.....</b>	<b>26</b>
The American Journal of Sports Medicine .....	26
British Journal of Sports Medicine.....	26
Emergency Medicine Journal .....	26
Spine .....	26
<b>Exercise: Creating a search strategy .....</b>	<b>27</b>
<b>Library Opening Times.....</b>	<b>28</b>



**UpToDate is the leading evidence-based clinical decision support system, designed for use at the point of care.**

It contains more than 9,500 searchable topics across the following specialities:

- ❖ Adult and paediatric emergency medicine
- ❖ Allergy and immunology
- ❖ Cardiovascular medicine
- ❖ Dermatology
- ❖ Drug therapy
- ❖ Endocrinology and diabetes mellitus
- ❖ Family medicine
- ❖ Gastroenterology and hepatology
- ❖ General surgery
- ❖ Geriatrics
- ❖ Haematology
- ❖ Hospital Medicine
- ❖ Infectious diseases
- ❖ Nephrology and hypertension
- ❖ Neurology
- ❖ Obstetrics and gynaecology
- ❖ Oncology
- ❖ Paediatrics
- ❖ Primary care internal medicine
- ❖ Psychiatry
- ❖ Pulmonary, critical care and sleep medicine
- ❖ Rheumatology

#### **How to access UpToDate**

You can access UpToDate from any computer via [www.uptodate.com](http://www.uptodate.com). You will need your NHS Athens username/password (register through <http://openathens.nice.org.uk/>).

## Updates

**NICE** National Institute for  
Health and Care Excellence

**[Accuracy of Physical Exam, Ankle-Brachial Index, and Ultrasonography in the Diagnosis of Arterial Injury in Patients with Penetrating Extremity Trauma: A Systematic Review and Meta-Analysis](#)**

Source: [PubMed](#) - 11 May 2017 - Publisher: Academic Emergency Medicine : Official Journal Of The Society For Academic Emergency Medicine [Read Summary](#)

**[Global burden of road traffic accidents in older adults: A systematic review and meta-regression analysis](#)**

Source: [PubMed](#) - 13 May 2017 - Publisher: Archives Of Gerontology And Geriatrics [Read Summary](#)

**[A Systematic Review of the Association Between Physical Fitness and Musculoskeletal Injury Risk: Part 1-Cardiorespiratory Endurance](#)**

Source: [PubMed](#) - 01 June 2017 - Publisher: Journal Of Strength And Conditioning Research [Read Summary](#)

**[Is soft tissue repair a right choice to avoid early dislocation after THA in posterior approach?](#)**

Source: [PubMed](#) - 19 May 2017 - Publisher: BMC Surgery [Read Summary](#)

**[Fractures of the ribs and pelvis](#)**

Source: [Finnish Medical Society Duodecim](#) - 11 May 2017 [Read Summary](#)

**[Peripheral nerve blocks for hip fractures](#)**

Source: [Cochrane Database of Systematic Reviews](#) - 11 May 2017 - Publisher: Cochrane Database of Systematic Reviews [Read Summary](#)

**[BTS Guideline for oxygen use in healthcare and emergency settings](#)**

Source: [British Thoracic Society - BTS](#) - 15 May 2017 - Publisher: British Thoracic Society (BTS) [Read Summary](#)



No relevant evidence

UpToDate®

OpenAthens login required. Register here: <https://openathens.nice.org.uk/>

#### What's new in emergency medicine

- [Treatment of nonpurulent cellulitis \(June 2017\)](#)
- [Treatment of acute diverticulitis without antibiotics \(February 2017\)](#)

#### Assessment and emergency management of the acutely agitated or violent adult

- [Violence prevention in the emergency department](#)
- [Summary and recommendations](#)

#### General principles of acute fracture management

- [Musculoskeletal ultrasound](#)
- [Summary and recommendations](#)

## Current Awareness Database Articles related to Musculoskeletal Soft Tissue

Below is a selection of articles recently added to the healthcare databases, grouped in the following categories:

- Acute Soft Tissue injuries
- Musculoskeletal
- Sports Injuries

If you would like any of the following articles in full text, or if you would like a more focused search on your own topic, then get in touch: [library@uhbristol.nhs.uk](mailto:library@uhbristol.nhs.uk)

### Acute soft tissue injuries

#### **Ballistic Trauma of Limbs.**

**Author(s):** Lamah, Léopold; Keita, Damany; Marie Camara, Ibrahima; Lamine Bah, Mohamed; Sory, Sidimé; Diallo, Mamadou Moustapha

**Source:** The open orthopaedics journal; 2017; vol. 11 ; p. 268-273

**Publication Type(s):** Journal Article

Available in full text at [Open Orthopaedics Journal, The](#) - from National Library of Medicine

**Abstract:**The objective of our study was to report the management and follow-up of a particular case of ballistic trauma and to do the literature review.OBSERVATIONA 35-year-old patient, a trader who was the victim of a firearm accident under not very clear circumstances. He was admitted to the

emergency department after 3 hours. Clinically, the patient had significant bleeding in the arm and was in a state of clouding of consciousness. We could notice on the right arm, a posterior large transfixing wound of 1 cm and a 6 cm one on the antero-internal side. The limb was cold with a small and thready pulse. Sensitivity was decreased in the radial nerve area. The radiograph showed bone comminution from the middle 1/3 to the superior 1/3 of the humeral diaphysis. The treatment was orthopedic (after debridement) by scapula-brachio-ante-brachiopalmar plaster splint with thoracic strap. The wound healed in 46 days and the patient resumed his activities after 11 months and 2 weeks. **CONCLUSION**The authors presented the value of using the scapulo-brachio-palmar plaster splints with thoracic strap in some severe upper limb trauma in the absence of the external fixator.

### **Irreducible Anterior Shoulder Dislocation with Interposition of the Long Head of the Biceps and Greater Tuberosity Fracture: A Case Report and Review of the Literature.**

**Author(s):** Pantazis, Konstantinos; Panagopoulos, Andreas; Tatani, Irini; Daskalopoulos, Basilis; Iliopoulos, Ilias; Tyllianakis, Minos

**Source:** The open orthopaedics journal; 2017; vol. 11 ; p. 327-334

**Publication Type(s):** Journal Article

Available in full text at [Open Orthopaedics Journal, The](#) - from National Library of Medicine

**Abstract:** **BACKGROUND** Failure of closed manipulative reduction of an acute anterior shoulder dislocation is seldom reported in the literature and is usually due to structural blocks such as soft tissue entrapment (biceps, subscapularis, labrum), bony fragments (glenoid, greater tuberosity) and severe head impaction (Hill-Sachs lesion). **CASE REPORT** We present a case of an irreducible anterior shoulder dislocation in a 57-year-old male patient after a road-traffic accident. He had severe impaction of the head underneath glenoid rim and associated fracture of the greater tuberosity. Closed reduction performed in the emergency room under sedation and later at the theatre under general anaesthesia was unsuccessful. Open reduction using the dectopectoral approach revealed that the reason for obstruction was the posterolateral entrapment of the biceps tendon between the humeral head and the tuberosity fragment. Reduction was achieved after subscapularis tenotomy and opening of the joint; the tuberosity fragment was fixed with transosseous sutures and the long head of the biceps tendon was tenodesized. The patient had an uneventful postoperative recovery and at his last follow up, 12 months postoperatively, he had a stable joint, full range of motion and a Constant score of 90. **CONCLUSION** A comprehensive literature review revealed 22 similar reports affecting a total of 30 patients. Interposition of the LHBT alone or in combination with greater tuberosity fracture was the most common obstacle to reduction, followed by subscapularis tendon interposition and other less common reasons. Early surgical intervention with open reduction and confrontation of associated injuries is mandatory for a successful outcome.

### **Dynamic intraligamentary stabilization versus conventional ACL reconstruction: A matched study on return to work**

**Author(s):** Bieri K.S.; Aghayev E.; Staub L.P.; Scholz S.M.; Kohl S.

**Source:** Injury; Jun 2017; vol. 48 (no. 6); p. 1243-1248

**Publication Type(s):** Article

**Abstract:** **Purpose** The dynamic intraligamentary stabilization (DIS) technique is based on a different treatment approach than ACL reconstruction in that it intends to promote self-healing of the ligament. It is only recommended for acute injuries (Copyright © 2017 Elsevier Ltd

### **Acute compartment syndrome caused by uncontrolled hypothyroidism.**

**Author(s):** Modi, Anar; Amin, Hari; Salzman, Matthew; Morgan, Farah

**Source:** The American journal of emergency medicine; Jun 2017; vol. 35 (no. 6); p. 937

**Publication Type(s):** Journal Article

**Abstract:** Acute compartment syndrome is increased tissue pressure exceeding perfusion pressure in a closed compartment resulting in nerve and muscle ischemia. Common precipitating causes are crush injuries, burns, substance abuse, osseous or vascular limb trauma. This is a case of 42-year-old female with history of hypothyroidism who presented to emergency room with acute onset of severe pain and swelling in right lower extremity. Physical examination was concerning for acute compartment syndrome of right leg which was confirmed by demonstration of elevated compartmental pressures. No precipitating causes were readily identified. Further laboratory testing revealed uncontrolled hypothyroidism. Management included emergent fasciotomy and initiating thyroid hormone replacement. This case represents a rare association between acute compartment syndrome and uncontrolled hypothyroidism. We also discuss the pathogenesis of compartment syndrome in hypothyroid patients and emphasize the importance of evaluating for less common causes, particularly in setting of non-traumatic compartment syndrome.

**Necrotizing fasciitis-A catastrophic complication following routine tibia fracture surgery: A case report and literature review.**

**Author(s):** Shang, Shuai; Zhang, Ruipeng; Hou, Zhiyong

**Source:** Medicine; Jun 2017; vol. 96 (no. 23); p. e6908

**Publication Type(s):** Case Reports Journal Article Review

**Abstract:** RATIONALE Necrotizing fasciitis (NF) is defined as a rare, life-threatening, rapidly spreading soft tissue infection resulting from a polymicrobial origin, with a predominance of anaerobic organisms that presents with necrosis of the muscle, fascia, and surrounding soft tissue. PATIENT CONCERNS AND DIAGNOSES A 64-year-old male who sustained tibia fracture caused by falling from a height underwent a tibia surgery with minimally invasive plate osteosynthesis technique in another institution. Postoperatively, the patient had development of a very uncommon NF at the site of the tibia procedure. When the patient was transferred to our unit, he rapidly progressed to toxic shock and coagulopathy. INTERVENTIONS AND OUTCOMES Although the patient underwent antibiotics treatment in the emergency room and was transferred to the operating room for surgery promptly, the patient's condition deteriorated rapidly and he died of septic shock and multiple organ failure unfortunately. LESSONS Our study aims to highlight the risk of NF in the elderly with diabetes during the perioperative period even if the injury is a simple closed fracture. Physicians must be vigilant to early inflammatory signs and pain in immunosuppressed patients.

**Unstable Open Posterior Subtalar Dislocation Treated With a Ring External Fixator: A Case Report and Review of the Literature.**

**Author(s):** Teo, Alex Quok An; Han, Fucai; Chee, Yu Han; O'Neill, Gavin Kane

**Source:** The Journal of foot and ankle surgery : official publication of the American College of Foot and Ankle Surgeons; Jun 2017

**Publication Type(s):** Journal Article

**Abstract:** Traumatic dislocation of the subtalar joint is an infrequently occurring injury, with open true posterior dislocation an even rarer injury. We describe our treatment of a young motorcyclist who was brought into hospital after a road traffic accident, having sustained an open posterior subtalar dislocation. After initial reduction and resuscitation in the emergency department, he was taken to the operating theater for emergent wound debridement and external fixation of his ankle using a unilateral external fixator device. After 2 subsequent repeat debridements, this was changed to a ring external fixator device, followed by split-thickness skin grafting of his wound. He was allowed full weightbearing and was discharged from hospital 10 days after his last operation. He continued to improve clinically at his outpatient appointments to the 1-year follow-up point, with his external fixator removed at 6 weeks postoperatively. At the last follow-up appointment, he had successfully returned to his previous employment. To the best of our knowledge, only 1 other description of an open posterior dislocation has been reported, which was managed nonoperatively



after wound debridement. Ours is the first reported case of an open posterior dislocation managed surgically using a ring external fixator. We believe the ability to allow immediate weightbearing resulting from the additional stability provided by this type of fixation is advantageous, with a theoretical reduction in the risk of periarticular osteoporosis and calf muscle atrophy. The early mobilization afforded by this treatment is hoped to improve the typically poor long-term outcomes for these patients.

#### **Long-term resolution of delayed onset hypoglossal nerve palsy following occipital condyle fracture: Case report and review of the literature**

**Author(s):** Vadivelu S.; Masood Z.; Krueger B.; Marciano R.; Chen D.; Houseman C.; Insinga S.

**Source:** Journal of Craniovertebral Junction and Spine; 2017; vol. 8 (no. 2); p. 149-152

**Publication Type(s):** Review

Available in full text at [Journal of Craniovertebral Junction and Spine](#) - from ProQuest

**Abstract:**The authors present the case of a patient that demonstrates resolution of delayed onset hypoglossal nerve palsy (HNP) subsequent to occipital condyle fracture following a motor vehicle accident. Decompression of the hypoglossal nerve and craniocervical fixation led to satisfactory long-term (>5 years) outcome. There is a scarcity of literature in recognizing HNPs following trauma and a lack of pathophysiological understanding to both a delayed presentation and to resolution versus persistence. This is the first report demonstrating long-term resolution of hypoglossal nerve injury following trauma to the craniocervical junction.

#### **The Unrecognized Epidemic of Electronic Cigarette Burns.**

**Author(s):** Ramirez, Jesus I.; Ridgway, Catherine A.; Lee, Jeanne G.; Potenza, Bruce M.; Sen, Soman; Palmieri, Tina L.; Greenhalgh, David G.; Maguina, Pirko

**Source:** Journal of Burn Care & Research; Jul 2017; vol. 38 (no. 4); p. 220-224

**Publication Type(s):** Academic Journal

**Abstract:**Electronic cigarettes (e-cigarettes) are novel battery-operated devices that deliver nicotine as an inhaled aerosol. They originated from China in 2007 and their use has rapidly increased worldwide in the past decade, yet they remain largely unregulated. Reports of injuries associated with their use have appeared as unusual events in the news media and as case reports in the medical literature. This study was undertaken to explore e-cigarettes as a mechanism of burn injury. **[ABSTRACT EDITED]**

#### **Complete femoral artery transection following handlebar trauma**

**Author(s):** Taneva Zaryanova G.T.; Arribas Diaz A.B.; Baeza Bermejillo C.; Aparicio Martinez C.; Gonzalez Garcia A.

**Source:** Trauma Case Reports; Jun 2017; vol. 9 ; p. 1-4

**Publication Date:** Jun 2017

**Publication Type(s):** Article

**Abstract:**Complete transection of the common femoral artery is more frequent after penetrating injuries than after blunt trauma, with most of the cases occurring in combination with fractures. Contusion from a bicycle handlebar is a rare form of injury to the femoral vessels. Hereby, we present a case of complete common femoral artery transection caused by a direct bicycle handlebar trauma. The patient suffered severe hypovolemia during his transfer to the Emergency room. He required an emergency intervention and a bypass reconstruction. Copyright © 2017 The Authors

**Database:** EMBASE

#### **Laparoscopic repair of a triple post-traumatic diaphragmatic injury**

**Author(s):** Zago M.; Bozzo S.; Coppola S.; Pirovano R.; Andretta M.; Ciocca Vasino M.

**Source:** Surgical Endoscopy and Other Interventional Techniques; Jun 2017; vol. 31 (no. 2)

**Publication Type(s):** Conference Abstract

**Abstract:** Aim: Laparoscopy is a currently the gold standard for ruling out/ruling in diaphragmatic injuries in case of thoracoabdominal penetrating trauma, in hemodynamically stable patients. Its diagnostic and therapeutical role is well documented. Notwithstanding, the laparoscopic approach for diaphragmatic injuries is considered challenging. The goal of this report is to show feasibility and technical aspects of the laparoscopic treatment of a strangulated diaphragmatic hernia with three muscular tears. Materials and Methods: We report the case of a 45 year-old man was admitted to the ED, in shock and severe respiratory distress. He was involved in road accident four weeks earlier, suffering multiple left ribs fractures, hemothorax and an amyelic fracture of the body of D10 vertebra. At that time, chest CT and chest X-ray did not show any sign of diaphragmatic injury. At re-admission, the chest X-ray showed the stomach in the left hemithorax, with hemo-pneumothorax and right dislocation of the mediastinum. A chest drain obtained partial recovery of both hemodynamics and respiratory distress. A thoracic CT confirmed a large diaphragmatic tear, with herniation of more than 2/3 of the stomach. Urgent surgery was undertaken. Results: A 5 ports laparoscopy confirmed the diagnosis of diaphragmatic hernia. Reduction of the strangulated stomach required a pre-cut near to the upper border of the apparently unique laceration. After gastric hernia reduction, three radial diaphragmatic tears were clearly found, with a length of 6, 3 and 1 cm respectively. Partial re-expansion of the lower pulmonary lobe was controlled before the deployment of a dependent left thoracic drainage. Repair of all muscular tears was performed with running sutures. Nonabsorbable monofilament was used for the longest and the shortest lacerations, an absorbable barbed stitch for the 3 cm long tear. Recovery was uneventful. Conclusion: Laparoscopy is the ideal approach for acute isolated diaphragmatic injuries in hemodynamically stable patients, and could be successful even in case of multiple lacerations and strangulated hollow viscus.

## Musculoskeletal

### **Staged Treatment of Infected Tibiotalar Fusion Using a Combination Antibiotic Spacer and Antibiotic-Coated Intramedullary Nail**

**Author(s):** Miller J.; Hoang V.; Yoon R.S.; Liporace F.A.

**Source:** Journal of Foot and Ankle Surgery; 2017

**Publication Date:** 2017

**Publication Type(s):** Article In Press

**Abstract:** Pilon fractures are notoriously difficult injuries to treat. The current published data on salvage procedures after failed pilon fractures includes both total ankle arthroplasty (TAA) and tibiotalar fusion, each with its own specific indications. However, no acceptable treatment algorithm addressing the complications of these limb salvage procedures is available. We present the case of a 23-year-old patient, who sustained a complex pilon fracture after a motor vehicle accident. The patient was referred to our institution after an initial fixation attempt, followed by subsequent failed TAA, which was complicated by an infected fusion attempt. We describe a staged treatment approach to clearing the infection and obtaining the final fusion goals. Copyright © 2017 American College of Foot and Ankle Surgeons.

### **Successful use of rivaroxaban in inferior vena cava thrombosis provoked by multiple traumatic injuries and surgeries: A case report**

**Author(s):** Kido K.; Noyes E.; Gutnik L.

**Source:** Journal of Clinical Pharmacy and Therapeutics; 2017

**Publication Type(s):** Article In Press

**Abstract:**What is known and objectives: There is a lack of consensus regarding optimal anticoagulation regimen and duration for inferior vena cava (IVC) thrombus due to the paucity of clinical evidence. A case of IVC thrombus treated with 3 months of rivaroxaban therapy is reported. Case description: Fifty-two-year-old male Caucasian presented following a motorcycle accident, with multiple left rib fractures requiring emergent amputation surgeries. During the hospitalization, he developed IVC thrombosis and completed 3 months of rivaroxaban treatment without any complication. The Doppler images at 6-week, 3-month and 6-month follow-up appointments showed no IVC thrombosis. What is new and conclusion: This is the first case of IVC thrombosis successfully treated with rivaroxaban. Further case series and clinical studies are needed to guide the use of direct oral anticoagulants for IVC thrombosis. Copyright © 2017 John Wiley & Sons Ltd.

**Dissection of the internal carotid artery and stroke after mandibular fractures: a case report and review of the literature.**

**Author(s):** Tveita, Ingrid Aune; Madsen, Martin Ragnar Skjerve; Nielsen, Erik Waage

**Source:** Journal of medical case reports; Jun 2017; vol. 11 (no. 1); p. 148

**Publication Type(s):** Journal Article

Available in full text at [Journal of Medical Case Reports](#) - from BioMed Central

**Abstract:**BACKGROUNDWe present a report of a patient with blunt trauma and mandibular fractures who developed a significant cerebral infarction due to an initially unrecognized injury of her left internal carotid artery. We believe that increased knowledge of this association will facilitate early recognition and hence prevention of a devastating outcome.CASE PRESENTATIONA 41-year-old ethnic Norwegian woman presented to our Emergency Room after a bicycle accident that had caused a direct blow to her chin. At admittance, her Glasgow Coma Scale was 15. Initial trauma computed tomography showed triple fractures of her mandible, but no further pathology. She was placed in our Intensive Care Unit awaiting open reduction of her mandibular fractures. During the following 9 hours, she showed recurrent episodes of confusion and a progressive right-sided hemiparesis. Repeated cerebral computed tomography revealed no further pathology compared to the initial scan. She had magnetic resonance angiography 17 hours after admittance, which showed dissection and thrombus formation in her left internal carotid artery, total occlusion of her left medial cerebral artery, and left middle cerebral artery infarction was detected.CONCLUSIONSCarotid artery dissection is a rare but life-threatening condition that can develop after trauma to the head and neck. There should be a high index of suspicion in patients with a mechanism of injury that places the internal carotid artery at risk because blunt vascular injury may show delayed onset with no initial symptoms of vascular damage. By implementing an algorithm for early detection and treatment of these injuries, serious brain damage may be avoided.

**Age-related mortality in blunt traumatic hemorrhagic shock: the killers and the life savers.**

**Author(s):** Hwabejire, John O; Nembhard, Christine E; Oyetunji, Tolulope A; Seyoum, Theodoros; Abiodun, Mayowa P; Siram, Suryanarayana M; Cornwell, Edward E; Greene, Wendy R

**Source:** The Journal of surgical research; Jun 2017; vol. 213 ; p. 199-206

**Publication Type(s):** Journal Article

**Abstract:**BACKGROUNDThere are sparse data on the association between age and mortality in hemorrhagic shock (HS). We examined this association in this study. **[ABSTRACT EDITED]**

**Severe pelvic fracture with profound hypotension: a case report and treatment algorithm.**

**Author(s):** Knight, Chadwick J; Wanko Mboumi, Igor; Thompson, Errington C

**Source:** Journal of surgical case reports; Jun 2017; vol. 2017 (no. 6); p. rjx093

**Publication Type(s):** Journal Article

Available in full text at [Journal of Surgical Case Reports](#) - from Highwire Press

**Abstract:** Approximately 9% of all blunt trauma patients suffer pelvic fractures. These fractures can range from insignificant and requiring almost no therapy to massive destruction of the pelvic ring with associated with multisystem injury and life-threatening hypotension which mandates the attention of the trauma surgeon, the orthopedic surgeon, the interventional radiologists and possibly other subspecialists. We present a case of a patient who presented to the emergency room in extremis from massive bleeding from a complex pelvic fracture. The patient developed abdominal compartment syndrome. The patient was emergently taken to the operating room but we were unable to control his pelvic bleeding. We propose an algorithm which might be helpful in these critically ill patients.

### **Metatarsal fracture leading to massive pulmonary embolism**

**Author(s):** Rajpurohit V.; Tejvir P.; Meena N.; Mittal K.

**Source:** Indian Journal of Critical Care Medicine; Jun 2017; vol. 21 (no. 6); p. 401-403

**Publication Type(s):** Article

Available in full text at [Indian Journal of Critical Care Medicine](#) - from ProQuest

**Abstract:** Immobilization and bed rest after fracture and orthopedic surgery are routinely advised protocol. Period of bed rest usually depends on the type of injury and orthopedic procedure, ranging from few days to weeks. The trauma, surgery, and immobilization with other contributing factors can lead to deep vein thrombosis and pulmonary embolism (PE) in these patients. Although there is high incidence of PE in such patients, it is difficult to diagnose, primarily because of the variety of nonspecific signs and symptoms. Here, we discuss a case of a 30-year-old female, who had suffered a trivial roadside accident leading to metatarsal bone fracture and later on presented in emergency with seizures, pulmonary edema, and cardiac arrest, after immobilization of just 5 days which was diagnosed to be result of massive PE. Here, we will discuss the pathophysiology, risk factors, and management of massive P.E.

### **Skull fracture with effacement of the superior sagittal sinus following drone impact: a case report**

**Author(s):** Chung L.K.; Cheung Y.; Lagman C.; Au Yong N.; McBride D.Q.; Yang I.

**Source:** Child's Nervous System; Jun 2017 ; p. 1-3

**Publication Type(s):** Article In Press

**Abstract:** Background: The popularity of unmanned aerial vehicles, or drones, raises safety concerns as they become increasingly common for commercial, personal, and recreational use. Collisions between drones and people may result in serious injuries. Case report: A 13-year-old male presented with a comminuted depressed skull fracture causing effacement of the superior sagittal sinus secondary to a racing drone impact. The patient experienced a brief loss of consciousness and reported lower extremity numbness and weakness after the accident. Imaging studies revealed bone fragments crossing the superior sagittal sinus with a short, focal segment of blood flow interruption. Neurosurgical intervention was deferred given the patient's improving neurological deficits, and the patient was treated conservatively. He was discharged home in stable condition. Conclusion: Drones may represent a hazard when operated inappropriately due to their capacity to fly at high speeds and altitudes. Impacts from drones can carry enough force to cause skull fractures and significant head injuries. The rising popularity of drones likely translates to an increased incidence of drone-related injuries. Thus, clinicians should be aware of this growing trend. Copyright © 2017 Springer-Verlag GmbH Germany

### **The first human clinical case of chronic osteomyelitis caused by Clostridium hydrogeniformans**

**Author(s):** Hirai J.; Fujita J.; Sakanashi D.; Suematsu H.; Hagihara M.; Kato H.; Yamagishi Y.; Mikamo H.; Huh J.Y.

**Source:** Anaerobe; Jun 2017; vol. 45 ; p. 138-141

**Publication Type(s):** Article

**Abstract:**We present the first case report of osteomyelitis due to *Clostridium hydrogeniformans* in a previously healthy 18-year-old male. He was admitted to our hospital because of an open contaminated fracture of the right arm after being blown into a drain in a motorbike accident. He underwent surgical debridement and treatment course of cefazolin. Although he responded well to these initial treatments, subcutaneous abscess and ulnar osteomyelitis developed 1 month after discharge. Second debridement was performed and specimens were collected from both the abscess and bone tissues. Only anaerobic culture showed a gas-producing Gam-positive rod. Conventional methods and matrix-assisted laser desorption/ionization time-of-flight mass spectrometry could not accurately identify this organism. However, 16S rRNA gene sequence analysis determined the isolate as *C. hydrogeniformans* with 99.79% homology. The patient recovered after 90 days of antibiotic treatment, and had no evidence of recurrence. Anaerobic bacteria are more common as causative pathogens in osteomyelitis related to traumatic wounds and *Clostridium* spp. are particularly associated with open fractures, which is consistent with our case. Although the epidemiology and clinical characteristics of *C. hydrogeniformans* infection is poorly understood because of the limitations of currently available conventional methods of identification, clinicians need to consider this organism as a causative pathogen in a patient with osteomyelitis in traumatic wounds, especially contaminated by sewer water. Copyright © 2017 Elsevier Ltd

#### **Basal ganglia infarction and striatal toe-a case report**

**Author(s):** Usar Incirli S.; Selcuk Muhtaroglu F.; Akbostanci C.

**Source:** Movement Disorders; Jun 2017; vol. 32 ; p. 830-831

**Publication Type(s):** Conference Abstract

**Abstract:**Objective: Pathology in the neostriatum (putamen and caudate) may cause deformities of the hand and foot. Striatal toe is a term used to describe the abnormal posture of the foot presenting with inversion and plantar flexion of the ankle and also with dorsiflexion of the great toe in the absence of corticospinal tract dysfunction symptoms. We report a young patient with striatal toe associated with posttraumatic head injury resulting with basal ganglia infarction whom foot deformity developed after the stroke. Methods: Case Report: Twenty nine years old male patient suffered from head injury due to a traffic accident brought to the emergency service. Neurologic examination showed confusion, agitation and mild left hemiparesis. Acute stage brain CT scan was normal where as control showed ischemia of the basal ganglia, suggesting posttraumatic stroke. Hemiparesis improved with physiotherapy but the patient began to develop abnormal posture of the foot. Neurologic examination showed striatal toe with inversion and dorsiflexion of the ankle and dorsiflexion of the great toe (figure 1). The abnormal posture persisted and did not alter during movement, rest and sleep and caused disabling gait disturbance. Cranial magnetic resonance imaging demonstrated chronic ischemic lesion in the putamen (figure 2). Conclusions: Hyperkinetic movement disorders are uncommon in acute stroke (1%) and are associated with lesions in the basal ganglia (44%) and thalamus (37%), characteristically present unilaterally in the contralateral side of the lesion. Amongst poststroke movement disorders dystonia is the most frequent one. Striatal toe is even a rarer condition seen due to caudate nucleus and putamen lesions. Deformity can interfere with dystonia and Babinski's sign. Unlike dystonia striatal toe persists during rest and sleep, does not alter with movement. Striatal toe is sometimes labelled as "pseudobabinski" and can be distinguish from pyramidal Babinski's sign by the presence of extensor plantar response without fanning of the toes. Striatal toe does not need a stimulus to appear whereas Babinski's sign is elicited when the sole of the foot is stimulated. (Figure Presented) .

#### **Autologous Blood Transfusion as a Life Saving Measure for a Trauma Patient with Fracture Femur and Drug Induced Hemolytic Anemia: A Case Report**

**Author(s):** Vishwakarma S.; Subramanian A.; Chaurasia R.; Chatterjee K.; Trikha V.

**Source:** Indian Journal of Hematology and Blood Transfusion; Jun 2017; vol. 33 (no. 2); p. 293-297

**Publication Date:** Jun 2017

**Publication Type(s):** Letter

**Abstract:** A positive direct antiglobulin test has been reported in 1:1000 to 1:14,000 blood donors and 1-15 % of hospital patients. Drugs may cause a positive direct antiglobulin test result and/or immune-mediated haemolysis with an incidence of approximately 1 in a 1 million population. Our aim is to highlight the importance of following strict transfusion protocols and management insight in a direct antiglobulin test positive patient showing incompatibility with multiple units possibly due to drug induced immune haemolytic anaemia (DIIHA). We also aim to highlight importance of autologous blood transfusion in an orthopaedic procedure in which homologous transfusion may be needed. We are presenting case of a 36 year old male with alleged h/o of road traffic accident with comminuted intra-articular fracture of the distal femur. He had h/o of ankylosing spondylitis since last 20 years on medication with indomethacin and methotrexate. A review of the literature was performed which showed use of drug methotrexate as an uncommon clinical entity for DIIHA; sporadic reports exist in the medical literature to support this view. The review of the literature in combination with our own data showed methotrexate can be a cause of DIIHA. We therefore advocate proper immunohaematological work up and use of autologous blood for management of at-risk-patients of DIIHA. Copyright © 2016, Indian Society of Haematology & Transfusion Medicine.

## Sports Injuries

### Simultaneous bilateral snowboarder's fractures in a young woman: A rare entity

**Author(s):** Barai A.; Scorgie R.; Lambie B.

**Source:** New Zealand Medical Journal; Jun 2017; vol. 130 (no. 1457); p. 79-83

**Publication Type(s):** Article

Available in full text at [New Zealand medical journal \[N Z Med J\] NLMUID: 0401067, The](#) - from EBSCOhost

**Abstract:** BACKGROUND: Talus is a well-supported bone in the foot. A fracture of talus requires a high-impact injury. A wedge-shaped inferolateral component is the lateral process of the talus (LPT). A fracture of LPT is also known as a 'snowboarder's fracture'. Simultaneous bilateral snowboarder's fracture is rarely reported in English literature. CASE: We present here a case of simultaneous bilateral snowboarder's fractures in a slow-moving motor vehicle accident in the icy conditions. The injuries were unique because the snowboarder's fractures were accompanied by fractures of the inferior aspect of talus bilaterally and a fracture of the anterior process of the calcaneus in the right foot. To our knowledge, no such case has been reported in the past. Our patient underwent successful open reduction and internal fixation with plate and screws. CONCLUSION: Snowboarder's fractures are frequently missed by the clinicians, which causes significant morbidity of the patients. Adequate knowledge and awareness among the physicians about this type of injury may improve the patient care. Copyright © NZMA.

### Goaltender.

**Author(s):** Degen, Ryan M; Fink, Matthew E; Callahan, Lisa; Fibel, Kenton; Ramsay, Jim; Kelly, Bryan T

**Source:** American journal of orthopedics (Belle Mead, N.J.); ; vol. 46 (no. 3); p. E139

**Publication Type(s):** Journal Article

**Abstract:** Internal carotid artery dissections are rare injuries that can result from both direct cervical trauma and indirect trauma causing sudden cervical hyperextension. Depending on the magnitude of the dissection, clinical presentation ranges from neurologic symptoms, such as Horner syndrome, to

relatively mild but persistent headache symptoms, as in the case reported in this article. High clinical suspicion with subsequent neuroimaging is recommended in similar clinical scenarios. Our patient, an ice hockey goaltender, was conservatively treated with rest and serial neuroimaging studies to ensure resolution of the dissection. Eight weeks later, he returned to athletic competition with resolved symptoms and radiologically improved arterial stenosis.

### **Don't Forget the Abdominal Wall: Imaging Spectrum of Abdominal Wall Injuries after Nonpenetrating Trauma.**

**Author(s):** Matalon, Shanna A; Askari, Reza; Gates, Jonathan D; Patel, Ketan; Sodickson, Aaron D;

**Source:** Radiographics : a review publication of the Radiological Society of North America, Inc; 2017; vol. 37 (no. 4); p. 1218-1235

**Publication Type(s):** Journal Article

**Abstract:**Abdominal wall injuries occur in nearly one of 10 patients coming to the emergency department after nonpenetrating trauma. Injuries range from minor, such as abdominal wall contusion, to severe, such as abdominal wall rupture with evisceration of abdominal contents. Examples of specific injuries that can be detected at cross-sectional imaging include abdominal muscle strain, tear, or hematoma, including rectus sheath hematoma (RSH); traumatic abdominal wall hernia (TAWH); and Morel-Lavallée lesion (MLL) (closed degloving injury). These injuries are often overlooked clinically because of (a) a lack of findings at physical examination or (b) distraction by more-severe associated injuries. However, these injuries are important to detect because they are highly associated with potentially grave visceral and vascular injuries, such as aortic injury, and because their detection can lead to the diagnosis of these more clinically important grave traumatic injuries. Failure to make a timely diagnosis can result in delayed complications, such as bowel hernia with potential for obstruction or strangulation, or misdiagnosis of an abdominal wall neoplasm. Groin injuries, such as athletic pubalgia, and inferior costochondral injuries should also be considered in patients with abdominal pain after nonpenetrating trauma, because these conditions may manifest with referred abdominal pain and are often included within the field of view at cross-sectional abdominal imaging. Radiologists must recognize and report acute abdominal wall injuries and their associated intra-abdominal pathologic conditions to allow appropriate and timely treatment. © RSNA, 2017.

### **High-Velocity Paint Gun Injuries**

**Author(s):** Wohltmann W.E.; Wisell J.A.; Lafrades C.M.C.; Cramer D.M.; Ragsdale B.D.

**Source:** American Journal of Dermatopathology; Jun 2017

**Publication Date:** Jun 2017

**Abstract:**ABSTRACT:: Cutaneous injuries due to industrial high-pressure paint guns are well-documented in the literature; however, the histologic characteristics are uncommonly described, and facial involvement has not been previously reported. Histopathologic features of paint gun injuries vary depending on the time since injection and type of material. Early lesions display an acute neutrophilic infiltrate, edema, and thrombosis, with varying degrees of skin, fat, and muscle necrosis. More developed lesions (120-192 hours after injury) have prominent histiocytes and fibrosis around necrotic foci, possibly with the pitfall of muscle regenerative giant cells that could be mistaken for sarcoma. Continuing inflammation, swelling, and resultant vascular compression could explain ongoing necrosis months after the accident. The histopathologic differential diagnosis in the absence of clinical history includes paint in an abrasion, foreign body reaction to tattoo, giant cell tumor of tendon sheath, and various neoplasms. If available, radiologic studies can substitute for clinical photographs to indicate the extent of injury. The radiologic differential, uninformed by history, may include calcific periartthritis, gouty tophus, and tumoral calcinosis. Seven cases of injury due to high-velocity paint guns are presented with 4 additional cases mimicking paint gun injury and with review of the literature. Copyright © 2017 Wolters Kluwer Health, Inc. All rights reserved.

**Peripheral nerve injuries: A retrospective survey of 1124 cases.****Author(s):** Kouyoumdjian, João A; Graça, Carla R; Ferreira, Vanessa F M**Source:** Neurology India; 2017; vol. 65 (no. 3); p. 551-555**Publication Type(s):** Journal ArticleAvailable in full text at [Neurology India \[Neurol India\] NLMUID: 0042005](#) - from EBSCOhost**Abstract:**BACKGROUND Peripheral nerve injuries (PNIs) remain an important health problem often leading to severe motor disabilities predominantly in the younger population. OBJECTIVE To analyze our experience of clinical and electrodiagnostic evaluation (EDX) of PNIs over a 26-year period.**[ABSTRACT EDITED]****Traumatic glaucoma due to paintball injuries: A case series****Author(s):** Lee K.M.; Seery C.; Khouri A.S.**Source:** Journal of Current Ophthalmology; 2017**Publication Type(s):** Article In Press**Abstract:** Purpose: To study the management and outcomes of patients with paintball injuries resulting in traumatic glaucoma. Methods: A retrospective review was performed, identifying four patients with a confirmed diagnosis of traumatic glaucoma secondary to paintball sports. Results: Four male patients with paintball gun injuries presented with a mean follow-up time of 51 months after the date of injury. The mean age was 23.5 +/- 18.6 years. Three patients presented with blunt trauma, while one patient had a ruptured globe. Presenting visual acuity (VA) was hand motions in three of the patients and no light perception in the fourth patient. All patients were diagnosed with traumatic glaucoma and treated with glaucoma medications during their follow-up. Two patients received tube shunts to control intraocular pressures (IOPs). At the time of most recent follow-up, three patients had elevated intraocular pressures and were not on any medications. Visual acuity at the last follow-up was 20/400 or worse. Conclusions: Traumatic glaucoma can be managed with surgical and medical interventions, while visual acuity usually does not return to baseline levels prior to the injury. Prognostic predictors can be used to guide treatment and identify patients who should be closely followed. Because the presentation and onset is widely variable, follow-up and screening is crucial even years after the injury. Copyright © 2017 Iranian Society of Ophthalmology.**Factors contributing to anterior cruciate ligament injury and pattern of presentations****Author(s):** Shah F.; Riaz M.U.; Hassan D.; Abbas Z.**Source:** Rawal Medical Journal; 2017; vol. 42 (no. 2); p. 223-225**Publication Type(s):** Article**Abstract:** Objectives: To determine the factors contributing to Anterior cruciate ligament (ACL) injury and their pattern of presentation. Methodology: This descriptive study included 45 patients diagnosed with ACL injury that were selected using non probability convenience sampling technique from department of orthopaedic and physical therapy of Mayo Hospital and Gurki Trust Hospital, Lahore, Pakistan. The study was completed in 6 months of duration. Subjects that were diagnosed with ACL injury using MRI with positive Lachman and Anterior Drawer test. Data regarding demographics, onset of injury, mechanism, occupational, recreational, daily routines and clinical presentations were recorded. Data were analysed by SPSS. Results: Out of 45 patients, 38(84.4%) cases were male and 7(16.5%) were female. 76% belonged to 20 to 30 age range. Regarding source of injury to anterior cruciate ligament, 32% got it during cricket, 21% during mild to severe road side accident, 20% during running and other 27% during daily life activities twisting, jumping and other high impact activities. The individual involved very often in high impact activities were 8%, often 13% and less often 79%. Conclusion: Major risk factors found were engaging in high impact activities such as sports, running and jumping nature. Clinical presentations were edema, decreased mobility, mild



to moderate pain and limited range of knee range of motion. Copyright © 2017, Pakistan Medical Association. All rights reserved.

### **Concussion management plan compliance a study of NCAA power 5 conference schools**

**Author(s):** Buckley T.A.; Difabio M.S.; Baugh C.M.; Meehan W.P.

**Source:** Orthopaedic Journal of Sports Medicine; 2017; vol. 5 (no. 4)

**Publication Date:** 2017

**Publication Type(s):** Article

Available in full text at [Orthopaedic Journal of Sports Medicine](#) - from Highwire Press

**Abstract:**Background: In response to concerns over concussions and repeated head impacts that occur during sports, the National Collegiate Athletic Association (NCAA) mandated that all member institutions enact a concussion management plan (CMP). Although institutional and health care provider self-reports have been investigated, compliance with NCAA protocol recommendations has not been examined. Purpose: To examine the CMPs from the 65 institutions within the NCAA Power 5 conferences for compliance with the NCAA 2015 concussion guidelines. Study Design: Descriptive epidemiology study. **[ABSTRACT EDITED]**

### **Computational modelling of traumatic brain injury predicts the location of chronic traumatic encephalopathy pathology**

**Author(s):** Ghajari M.; Hellyer P.J.; Sharp D.J.

**Source:** Brain; 2017; vol. 140 (no. 2); p. 333-343

**Publication Date:** 2017

**Publication Type(s):** Article

**PubMedID:** 28043957

Available in full text at [Brain](#) - from Highwire Press

**Abstract:**Traumatic brain injury can lead to the neurodegenerative disease chronic traumatic encephalopathy. This condition has a clear neuropathological definition but the relationship between the initial head impact and the pattern of progressive brain pathology is poorly understood. We test the hypothesis that mechanical strain and strain rate are greatest in sulci, where neuropathology is prominently seen in chronic traumatic encephalopathy, and whether human neuroimaging observations converge with computational predictions. **[ABSTRACT EDITED]**

### **Patient response to an integrated orthotic and rehabilitation initiative for traumatic injuries: The PRIORITI-MTF study**

**Author(s):** Hsu J.R.; Owens J.G.; Ferguson J.R.; Stinner D.J.; Wilken J.M.; DeSanto J.; Huang Y.;

**Source:** Journal of Orthopaedic Trauma; 2017; vol. 31

**Publication Type(s):** Article

**Abstract:**Although limb salvage is now possible for many high-energy open fractures and crush injuries to the distal tibia, ankle, hindfoot, and midfoot, orthotic options are limited. The Intrepid Dynamic Exoskeletal Orthosis (IDEO) is a custom, energy-storing carbon fiber orthosis developed for trauma patients undergoing limb salvage. The IDEO differs from other orthoses in that it allows patients with ankle weakness to have more normal ankle biomechanics and increased ankle power. This article describes the design of a study to evaluate the effectiveness of the IDEO when delivered together with a high-intensity, sports medicine-based approach to rehabilitation. It builds on earlier studies by testing the program at military treatment facilities beyond the Brooke Army Medical Center and the Center for the Intrepid where the device was developed. **[ABSTRACT EDITED]**

### **Outcomes after arthroscopic Bankart repair in adolescent athletes participating in collision and contact sports**

**Author(s):** Saper M.G.; Milchteim C.; Zondervan R.L.; Andrews J.R.; Ostrander R.V.

**Source:** Orthopaedic Journal of Sports Medicine; 2017; vol. 5 (no. 3)

**Publication Type(s):** Article

Available in full text at [Orthopaedic Journal of Sports Medicine](#) - from Highwire Press

**Abstract:**Background: Literature on arthroscopic stabilization in adolescent patients participating in collision and contact sports is limited, as most studies include adolescents within a larger sample group comprised primarily of adults. Purpose: To review the outcomes of arthroscopic Bankart repair for anterior shoulder instability in an adolescent population participating in collision and contact sports. Study Design: Case series; Level of evidence, 4. **[ABSTRACT EDITED]**

### **New approach for sportsman hernia; integration of surgery with muscles sport rehabilitation**

**Author(s):** Dudai M.

**Source:** Hernia; 2017; vol. 21 (no. 1)

**Publication Date:** 2017

**Publication Type(s):** Conference Abstract

**Abstract:**Sport Groin injuries are common among professional Athletes but also in sport active people. In part is treated by Conservative treatment and in part by Surgery. In some of the cases there are more complexes injury that will need combined Endoscopic surgery with conservative treatments. There are two kinds of Sport Groin Injury (SGI); Sportsman Hernia (SH) and Athletes Pubalgia (AP). The pathology of SH is sport trauma causing small and irreversible tears in the posterior inguinal wall while in the AP there is a stress injury with edema and inflammation in the Pubic Bone and its muscles attachment. Surgery is the only proved effective treatment for SH. Endoscopic TEP pressure releasing and posterior wall mesh reinforcement is the recommended treatment. On the other hand, conservative treatment is recommended for AP. In our experience we found that 70% of the athletes presenting with findings of both types of SGI: SH is persistently bilateral but PBSI expressed in different level of severity; grade 1-5. We discovered that the SH is the first injury and because the athlete continues with extreme sport activities on top of the SH injury, others PBSI be caused. We build up a program that is Endoscopic TEP release and reinforce of the posterior wall combined with Muscles Sport Rehabilitation Program (SMRP). We had found that the effective and shorter recovery combination is starting with the surgery, repairing and giving strength to the groin that act as an anchor for the muscles and enabling the SMRP. Athletes suffered from SGI have to be diagnosed correctly. Many of them having both SH and AP, in these cases combined treatments of Endoscopy followed by MSRP has to be recommended. If the right treatment is selected the results are excellent with less than 0.5% persistent pain after returning to sport activity.

### **Public Medical Preparedness at the "Swiss Wrestling and Alpine Games 2013": Descriptive Analysis of 1,533 Patients Treated at the Largest 3-Day Sporting Event in Switzerland**

**Author(s):** Hostettler-Blunier S.; Exadaktylos A.; Bahler H.; Neff F.; Baumberger D.; Muller N.; Haltmeier T.; Schnuriger B.; Hosner A.

**Source:** Emergency Medicine International; 2017; vol. 2017

**Publication Type(s):** Conference Paper

**Abstract:**Introduction. Medical preparedness at mass gatherings is challenging, as little is known about the optimal planning. Most studies and case reports are based on mass casualty incidents, so the results cannot be extrapolated to mass gatherings. Aim of this study was to evaluate the preclinical medical structure and the frequency of specific injuries and medical emergencies during the event. **[ABSTRACT EDITED]**

### **Traumatic sports-related cervical spine injuries**

**Author(s):** Puvanesarajah V.; Qureshi R.; Cancienne J.M.; Hassanzadeh H.

**Source:** Clinical Spine Surgery; 2017; vol. 30 (no. 2); p. 50-56

**Publication Type(s):** Review

**Abstract:** Cervical spine trauma in the athlete is not an insignificant occurrence with possibly catastrophic results. Football remains one of the most common and most well studied sporting activities associated with spine injuries. Transient spinal cord and peripheral nerve injuries may manifest as quadriplegia or burners/stingers with symptoms that resolve completely. More severe spinal cord injuries, typically from axial loading on the cervical spine, will cause bilateral symptoms with residual neurological deficit. Acute Trauma Life Support principles must always be applied to the player with a potential spine injury. Recent positional statements by National Athletic Trainers' Association advocate equipment removal on the field by 3 individuals with appropriate training, a shift from previous recommendations. This recommendation is still under debate, but equipment removal in the field is an option depending on staff training. The use of steroids in acute spinal cord injury remains controversial. Moderate systemic hypothermia has theoretical benefits for reducing spinal cord damage in the setting of an acute injury. Although it has been studied in the laboratory, only a few clinical trials have been performed and further research is necessary before routine implementation of hypothermia protocols. Copyright © 2016 Wolters Kluwer Health, Inc. All rights reserved.

### **Retrospective Analysis of Mosh-Pit-Related Injuries.**

**Author(s):** Milsten, Andrew M; Tennyson, Joseph; Weisberg, Stacy

**Source:** Prehospital and disaster medicine; Jul 2017 ; p. 1-6

**Publication Type(s):** Journal Article

**Abstract:** OBJECTIVES Moshing is a violent form of dancing found world-wide at rock concerts, festivals, and electronic dance music events. It involves crowd surfing, shoving, and moving in a circular rotation. Moshing is a source of increased morbidity and mortality. The goal of this study was to report epidemiologic information on patient presentation rate (PPR), transport to hospital rate (TTHR), and injury patterns from patients who participated in mosh-pits. **[ABSTRACT EDITED]**

### **Chronic Anterior Pelvic Instability: Diagnosis and Management.**

**Author(s):** Stover, Michael D; Edelstein, Adam I; Matta, Joel M

**Source:** The Journal of the American Academy of Orthopaedic Surgeons; Jul 2017; vol. 25 (no. 7); p. 509-517

**Publication Type(s):** Journal Article

**Abstract:** Chronic anterior pelvic ring instability can cause pain and disability. Pain typically is localized to the suprapubic area or inner thigh; often is associated with lower back or buttock pain; and may be exacerbated by activity, direct impact, or pelvic ring compression. Known etiologies of chronic anterior pelvic ring instability include pregnancy, parturition, trauma, insufficiency fractures, athletics, prior surgery, and osteitis pubis. Diagnosis often is delayed. Physical examination may reveal an antalgic or waddling gait, tenderness over the pubic bones or symphysis pubis, and pain with provocative maneuvers. AP pelvic radiographs may demonstrate chronic degenerative changes at the pubic symphysis or nonhealing fractures. Standing single leg stance (flamingo view) radiographs can demonstrate pathologic motion at the pubic symphysis. CT may be useful in assessing posterior pelvic ring involvement. The initial management is typically nonsurgical and may include the use of an orthosis, activity modification, medication, and physical therapy. If nonsurgical modalities are unsuccessful, surgery may be warranted, although little evidence exists to guide treatment. Surgical intervention may include internal fixation alone in select patients, the addition of

bone graft to fixation, or symphyseal arthrodesis. In some patients, additional stabilization or arthrodesis of the posterior pelvic ring may be indicated.

**Dizziness, Unsteadiness, Visual Disturbances, and Sensorimotor Control in Traumatic Neck Pain.**

**Author(s):** Treleaven, Julia

**Source:** The Journal of orthopaedic and sports physical therapy; Jul 2017; vol. 47 (no. 7); p. 492-502

**Publication Type(s):** Journal Article

**Abstract:**Synopsis There is considerable evidence to support the importance of cervical afferent dysfunction in the development of dizziness, unsteadiness, visual disturbances, altered balance, and altered eye and head movement control following neck trauma, especially in those with persistent symptoms. However, there are other possible causes for these symptoms, and secondary adaptive changes should also be considered in differential diagnosis. Understanding the nature of these symptoms and differential diagnosis of their potential origin is important for rehabilitation. In addition to symptoms, the evaluation of potential impairments (altered cervical joint position and movement sense, static and dynamic balance, and ocular mobility and coordination) should become an essential part of the routine assessment of those with traumatic neck pain, including those with concomitant injuries such as concussion and vestibular or visual pathology or deficits. Once adequately assessed, appropriate tailored management should be implemented. Research to further assist differential diagnosis and to understand the most important contributing factors associated with abnormal cervical afferent input and subsequent disturbances to the sensorimotor control system, as well as the most efficacious management of such symptoms and impairments, is important for the future. J Orthop Sports Phys Ther 2017;47(7):492-502. Epub 16 Jun 2017. doi:10.2519/jospt.2017.7052.

**Proximal peroneus longus tear: rare case in a teenage athlete and review of the literature.**

**Author(s):** Winfeld, Matthew; Chauvin, Nancy

**Source:** Skeletal radiology; Jul 2017; vol. 46 (no. 7); p. 1007-1009

**Publication Type(s):** Journal Article

**Abstract:**We present the case of a 15-year-old teenager who sustained an ankle inversion injury while playing American football, which yielded only minimal pain, but also foot numbness and a lateral leg bulge. Magnetic resonance imaging evaluation revealed a proximal peroneal tear. These rare injuries are often associated with compartment syndrome, a surgical emergency, which was ultimately excluded clinically in this patient. Relevant anatomy, mechanism of injury, and clinical manifestations are discussed.

**Exposure to Surgery and Anesthesia After Concussion Due to Mild Traumatic Brain Injury.**

**Author(s):** Abcejo, Arnoley S; Savica, Rodolfo; Lanier, William L; Pasternak, Jeffrey J

**Source:** Mayo Clinic proceedings; Jul 2017; vol. 92 (no. 7); p. 1042-1052

**Publication Type(s):** Journal Article

Available in full text at [Mayo Clinic Proceedings](#) - from ProQuest

**Abstract:**OBJECTIVETo describe the epidemiology of surgical and anesthetic procedures in patients recently diagnosed as having a concussion due to mild traumatic brain injury. **[ABSTRACT EDITED]**

**Longitudinal change in patellofemoral cartilage thickness, cartilage T2 relaxation times, and subchondral bone plate area in adolescent vs mature athletes.**

**Author(s):** Culvenor, Adam G; Wirth, Wolfgang; Maschek, Susanne; Boeth, Heide; Diederichs, Gerd; Duda, Georg; Eckstein, Felix

**Source:** European journal of radiology; Jul 2017; vol. 92 ; p. 24-29

**Publication Type(s):** Journal Article

**Abstract:**OBJECTIVEPatellofemoral cartilage changes have been evaluated in knee trauma and osteoarthritis; however, little is known about changes in patellar and trochlear cartilage thickness, T2 relaxation-time and subchondral bone plate area (tAB) during growth. Our prospective study aimed to explore longitudinal change in patellofemoral cartilage thickness, T2 and tAB in adolescent athletes, and to compare these data with those of mature (i.e., adult) athletes. **[ABSTRACT EDITED]**

**Preventing overuse shoulder injuries among throwing athletes: a cluster-randomised controlled trial in 660 elite handball players.**

**Author(s):** Andersson, Stig Haugsboe; Bahr, Roald; Clarsen, Benjamin; Myklebust, Grethe

**Source:** British journal of sports medicine; Jul 2017; vol. 51 (no. 14); p. 1073-1080

**Publication Type(s):** Journal Article

Available in full text at [British Journal of Sports Medicine](#) - from Highwire Press

**Abstract:**BACKGROUNDShoulder problems are highly prevalent among elite handball players. Reduced glenohumeral rotation, external rotation weakness and scapula dyskinesis have been identified as risk factors.AIMEvaluate the effect of an exercise programme designed to reduce the prevalence of shoulder problems in elite handball. **[ABSTRACT EDITED]**

**Vascular Quadrilateral Space Syndrome in 3 Overhead Throwing Athletes: An Underdiagnosed Cause of Digital Ischemia.**

**Author(s):** Rollo, Johnathon; Rigberg, David; Gelabert, Hugh

**Source:** Annals of vascular surgery; Jul 2017; vol. 42; p. 63

**Publication Type(s):** Journal Article

**Abstract:**Vascular quadrilateral space syndrome (vQSS) is an underdiagnosed cause of extremity ischemia, pain, and paresthesia in overhand throwing athletes. The mechanism of vQSS is thought to result from repeated abduction and external rotation of the arm leading to a distraction injury of the posterior circumflex humoral artery (PCHA) as this courses through the quadrilateral space. This trauma may cause dissection and dissecting aneurysm formation. Thrombus from this arterial injury then embolizes down the arm resulting in the symptomatic presentation. Patients were often presented after multiple embolic events, which have resulted in obliteration of digital arteries. Later stages of presentation may include ischemic ulceration and gangrene. We report 3 cases of vQSS in overhand throwing athletes. **[ABSTRACT EDITED]**

**Diagnostic accuracy of tablet-based software for the detection of concussion**

**Author(s):** Yang S.; Le W.; Peacock W.F.; Flores B.; Magal R.; Harris K.; Gross J.; Ewbank A.; Davenport S.; Ormachea P.; Nasser W.; Katz Y.; Eagleman D.M.

**Source:** PLoS ONE; Jul 2017; vol. 12 (no. 7)

**Publication Type(s):** Article

Available in full text at [PLoS ONE](#) - from National Library of Medicine

**Abstract:**Despite the high prevalence of traumatic brain injuries (TBI), there are few rapid and straightforward tests to improve its assessment. To this end, we developed a tablet-based software battery ("BrainCheck") for concussion detection that is well suited to sports, emergency department, and clinical settings. This article is a study of the diagnostic accuracy of BrainCheck. **[ABSTRACT EDITED]**

**Hip and Pelvis: MRI of Musculotendinous Trauma and Mimickers**

**Author(s):** Tsifountoudis I.; Kraniotis P.; Karantanas A.H.

**Source:** Seminars in Musculoskeletal Radiology; Jul 2017; vol. 21 (no. 3); p. 218-239

**Publication Type(s):** Article

**Abstract:**The spectrum of disorders in musculotendinous trauma (MTt) includes acute traumatic and subacute/chronic lesions caused by repetitive microtrauma. The imaging findings differ in the immature versus the mature skeleton in both categories. Sport-related MTt also depends on age, sex, and type of activity. Magnetic resonance imaging (MRI) is the modality of choice for exploring most MTt injuries and is invaluable for assessing severity and for planning management and return to activity. In some circumstances such as minimally displaced avulsion injuries, MRI findings need to be matched with plain radiographs or computed tomography. Ultrasonography is helpful in exploring superficial structures such as tendons, particularly if dynamic studies are required. Rarely, inflammatory or neoplastic disorders may simulate MTt in the hip and pelvis. Copyright © 2017 by Thieme Medical Publishers, Inc.

**Outcomes After Percutaneous Reduction and Fixation of Low-Energy Lisfranc Injuries.**

**Author(s):** Vosbikian, Michael; O'Neil, Joseph T.; Piper, Christine; Huang, Ronald; Raikin, Steven M.

**Source:** Foot & Ankle International; Jul 2017; vol. 38 (no. 7); p. 710-715

**Publication Type(s):** Academic Journal

**Abstract:**Background: Lisfranc injuries are often missed initially or not anatomically reduced, leading to midfoot collapse, arthrosis, and pain. Operative management of these injuries is also fraught with complications, particularly with respect to the soft tissues. Wound dehiscence and infection are not uncommon. The goal of this study was to analyze the outcomes of a minimally invasive technique in reduction and percutaneous fixation of low-energy minimally displaced Lisfranc injuries and determine if it is a safe alternative to more traditional, open approaches. **[ABSTRACT EDITED]**

**The peculiar properties of the falx and tentorium in brain injury biomechanics.**

**Author(s):** Ho, Johnson; Zhou, Zhou; Li, Xiaogai; Kleiven, Svein

**Source:** Journal of biomechanics; Jun 2017

**Publication Type(s):** Journal Article

**Abstract:**The influence of the falx and tentorium on brain injury biomechanics during impact was studied with finite element (FE) analysis. Three detailed 3D FE head models were created based on the images of a healthy, normal size head. Two of the models contained the addition of falx and tentorium with material properties from previously published experiments. Impact loadings from a reconstructed concussive case in a sport accident were applied to the two players involved. The results suggested that the falx and tentorium could induce large strains to the surrounding brain tissues, especially to the corpus callosum and brainstem. The tentorium seemed to constrain the motion of the cerebellum while inducing large strain in the brainstem in both players involved in the accident (one player had mainly coronal head rotation and the other had both coronal and transversal rotations). Since changed strain levels were observed in the brainstem and corpus callosum, which are classical sites for diffuse axonal injuries (DAI), we confirmed the importance of using accurate material properties for falx and tentorium in a FE head model when studying traumatic brain injuries.

**Searching for the "sweet spot": the foot rotation and parallel engagement of ankle ligaments in maximizing injury tolerance.**

**Author(s):** Nie, Bingbing; Forman, Jason L; Mait, Alexander R; Donlon, John-Paul; Panzer, Matthew B; Kent, Richard W

**Source:** Biomechanics and modeling in mechanobiology; Jun 2017

**Publication Type(s):** Journal Article

**Abstract:**Ligament sprains, defined as tearing of bands of fibrous tissues within ligaments, account for a majority of injuries to the foot and ankle complex in field-based sports. External rotation of the

foot is considered the primary injury mechanism of syndesmotic ankle sprains with concomitant flexion and inversion/eversion associated with particular patterns of ligament trauma. However, the influence of the magnitude and direction of loading vectors to the ankle on the in situ stress state of the ligaments has not been quantified in the literature. The objective of the present study was to search for the maximum injury tolerance of a human foot with an acceptable subfailure distribution of individual ligaments. **[ABSTRACT EDITED]**

**Distal triceps injuries (including snapping triceps): A systematic review of the literature.**

**Author(s):** Shuttlewood, Kimberley; Beazley, James; Smith, Christopher D

**Source:** World journal of orthopedics; Jun 2017; vol. 8 (no. 6); p. 507-513

**Publication Date:** Jun 2017

**Abstract:**AIMTo review current literature on types of distal triceps injury and determine diagnosis and appropriate management. **[ABSTRACT EDITED]**

**A prospective transcranial Doppler ultrasound-based evaluation of the acute and cumulative effects of sport-related concussion on neurovascular coupling response dynamics.**

**Author(s):** Wright, Alexander D; Smirl, Jonathan D; Bryk, Kelsey; van Donkelaar, Paul

**Source:** Journal of neurotrauma; Jun 2017

**Publication Type(s):** Journal Article

**Abstract:**Sport-related concussion has been shown to alter cerebral blood flow (CBF) both acutely and chronically, and may exert cumulative effects across multiple injuries. Such dysfunction may be mediated by trauma-induced deficits to CBF control mechanisms, though our understanding of these effects is limited, including dynamics of neurovascular coupling (NVC) responses (i.e. CBF responses to neurologic demand). **[ABSTRACT EDITED]**

**Recreational Activity and Facial Trauma Among Older Adults.**

**Author(s):** Plawewski, Andrea; Bobian, Michael; Kandinov, Aron; Svider, Peter F; Folbe, Adam J; Eloy, Jean Anderson; Carron, Michael

**Source:** JAMA facial plastic surgery; Jun 2017

**Publication Type(s):** Journal Article

Available in full text at [JAMA facial plastic surgery \[JAMA Facial Plast Surg\] NLMUID: 101589532](#) - from EBSCOhost

**Abstract:**ImportanceAs the US population ages, public health agencies have released guidelines encouraging aerobic activity and muscle-strengthening exercises among older individuals. Facial trauma from such activities among elderly individuals has long been underappreciated.ObjectivesTo evaluate the incidence of recreational activity-associated facial fractures among older adults and to further delineate injury characteristics including demographics, fracture location, and specific activities. **[ABSTRACT EDITED]**

**Blunt laryngeal trauma secondary to sporting injuries.**

**Author(s):** Mendis, D; Anderson, J A

**Source:** The Journal of laryngology and otology; Jun 2017 ; p. 1-8

**Publication Type(s):** Journal Article

**Abstract:**BACKGROUNDLaryngeal injury after blunt trauma is uncommon, but can cause catastrophic airway obstruction and significant morbidity in voice and airway function. This paper aims to discuss a case series of sports-related blunt laryngeal trauma patients and describe the results of a thorough literature review. **[ABSTRACT EDITED]**

**Retinal detachment associated with basketball-related eye trauma.**

**Author(s):** Lee, Tsung-Han; Chen, Yi-Hao; Kuo, Hsi-Kung; Chen, Yung-Jen; Chen, Chih-Hsin; Lee, Jong-Jer; Wu, Pei-Chang

**Source:** American journal of ophthalmology; Jun 2017

**Publication Type(s):** Journal Article

**Abstract:**PURPOSEBasketball is a popular sport involving significant body contact, which may frequently result in ocular trauma. The aim of this study was to evaluate the characteristics and visual outcomes of retinal detachment associated with basketball-related injury.DESIGNRetrospective, interventional case series. **[ABSTRACT EDITED]**

**Ankle Morel-Lavallée lesion in a recreational racquetball player.**

**Author(s):** Khodaei, Morteza; Deu, Rajwinder S

**Source:** The Journal of sports medicine and physical fitness; Jun 2017; vol. 57 (no. 6); p. 822-824

**Publication Type(s):** Journal Article

**Abstract:**Unilateral ankle swelling is a relatively common presenting complaint among athletes and non-athletes. Due to its broad differential diagnosis, a comprehensive evaluation beginning with history and physical examination are recommended. Imaging including plain radiography, ultrasound (US), and magnetic resonance imaging (MRI) are preferred modalities. Aspiration of a local fluctuating mass may help with the diagnosis and management of some of these conditions. **[ABSTRACT EDITED]**

**Risk Factors for Tear Progression in Symptomatic Rotator Cuff Tears: A Prospective Study of 174 Shoulders.**

**Author(s):** Yamamoto, Nobuyuki; Mineta, Mitsuyoshi; Kawakami, Jun; Sano, Hiroataka; Itoi, Eiji

**Source:** The American journal of sports medicine; Jun 2017 ; p. 363546517709780

**Publication Type(s):** Journal Article

**Abstract:**BACKGROUNDThe risk factors for tear progression in symptomatic rotator cuff tears have not been clarified yet. It is important for orthopaedic surgeons to know the natural course of tear progression when nonoperative management is to be chosen.HYPOTHESISTears in younger patients, high-activity patients, or heavy laborers would progress in size more than those in older patients, low-activity patients, or light laborers. **[ABSTRACT EDITED]**

**Overuse Injuries in Professional Ballet: Influence of Age and Years of Professional Practice.**

**Author(s):** Sobrino, Francisco José; Guillén, Pedro

**Source:** Orthopaedic journal of sports medicine; Jun 2017; vol. 5 (no. 6); p. 2325967117712704

**Publication Date:** Jun 2017

**Publication Type(s):** Journal Article

**PubMedID:** 28695138

Available in full text at [Orthopaedic Journal of Sports Medicine](#) - from Highwire Press

**Abstract:**BACKGROUNDIn spite of the high rate of overuse injuries in ballet dancers, no studies have investigated the prevalence of overuse injuries in professional dancers by providing specific diagnoses and details on the differences in the injuries sustained as a function of age and/or years of professional practice.HYPOTHESISOveruse injuries are the most prevalent injuries in ballet dancers. Professional ballet dancers suffer different types of injuries depending on their age and years of professional practice.STUDY DESIGNDescriptive epidemiology study. **[ABSTRACT EDITED]**



**Non-surgical treatment of pubic overload and groin pain in amateur football players: a prospective double-blinded randomised controlled study.**

**Author(s):** Schöberl, M; Prantl, L; Loose, O; Zellner, J; Angele, P; Zeman, F; Spreitzer, M; Nerlich, M; Krutsch, W

**Source:** Knee surgery, sports traumatology, arthroscopy : official journal of the ESSKA; Jun 2017; vol. 25 (no. 6); p. 1958-1966

**Publication Type(s):** Journal Article

**Abstract:**PURPOSEThe incidence of groin pain in athletes is steadily increasing. Symptomatic pubic overload with groin pain and aseptic osteitis pubis represent well-known and frequently misdiagnosed overuse injuries in athletes. This study investigated the benefits of standardised non-surgical treatment for swift return-to-football. **[ABSTRACT EDITED]**

**Comprehensive Headache Experience in Collegiate Student-Athletes: An Initial Report From the NCAA Headache Task Force.**

**Author(s):** Seifert, Tad; Sufrinko, Alicia; Cowan, Robert; Scott Black, W; Watson, Dave; Edwards, Bill;

**Source:** Headache; Jun 2017; vol. 57 (no. 6); p. 877-886

**Publication Date:** Jun 2017

**Abstract:**BACKGROUNDThe prevalence of primary headache disorders in the general population provides a unique challenge in the evaluation of headache occurring in the context of sport. Despite a wealth of studies exploring the epidemiology of headache in the layperson, little is known about the prevalence and nature of headaches in collegiate student-athletes. These scenarios are challenging in the return to play context, as it is often unclear whether an athlete has an exacerbation of a primary headache disorder, new onset headache unrelated to trauma, or has suffered a concussive injury.PURPOSETo establish the prevalence and nature of headaches in collegiate student-athletes. **[ABSTRACT EDITED]**

**Kickboxing review: anthropometric, psychophysiological and activity profiles and injury epidemiology.**

**Author(s):** Slimani, M; Chaabene, H; Miarka, B; Franchini, E; Chamari, K; Cheour, F

**Source:** Biology of sport; Jun 2017; vol. 34 (no. 2); p. 185-196

**Publication Type(s):** Journal Article Review

**Abstract:**Kickboxing is one of the modern combat sports. The psychophysiological demands of a kickboxing competition require athletes to achieve high thresholds of several aspects of physical fitness. The aim of the current review is to critically analyse and appraise the kickboxer's anthropometric, physiological, physical and psychological attributes with the activity profile and injury epidemiology in order to provide practical recommendations for training as well as new areas of scientific research. The available information shows that both amateur and elite-level male kickboxers are characterized by a higher proportion of mesomorphy with a well-developed muscle mass and low body fat percentage. While there is some variation in the maximum oxygen uptake of kickboxers, moderate to high cardio-respiratory levels are reported for these athletes. Regardless of kickboxers' level, a high peak and mean anaerobic power output were reported. High-level kickboxing performance also requires well-developed muscle power in both the upper and lower limbs. Psychological factors contribute to success that requires high levels of self-confidence, motivation, dispositional hope and optimism, mental toughness/resiliency, and adaptive perfectionism. Psychological attributes also distinguished successful from less successful kickboxers. The activity-to-rest ratio was higher in elite (1:1) than both amateur and national-level (from 1:2 to 1:5) kickboxers, with no significant differences between rounds (round 1=1:4, and rounds 2 and 3=1:5) as well as between winners and losers in amateur and national-level simulated combats. These particular psychophysiological characteristics and performance aspects of kickboxers influence

performance and could serve as guidance for training. Finally, kickboxing is characterized by chronic repetitive head trauma, which causes hypopituitarism due to traumatic brain injury (TBI). Future investigations into the physical, physiological and psychological characteristics related to age, gender and competitive levels of kickboxers are required to enrich the current knowledge and to help create the most suitable training programme.

**Great exSPECT-CTations: Hybrid imaging in traumatic wrist injuries**

**Author(s):** Dalili D.; Ilyas H.; Adamson K.; Ul-Hassan F.; Eccles A.; Isaac A.

**Source:** Skeletal Radiology; Jun 2017; vol. 46 (no. 6); p. 857

**Publication Type(s):** Conference Abstract

**Abstract:** Purpose: To establish the added value of SPECT/CT in wrist trauma. Reflecting on a decade of practice, we compare and correlate the significance of SPECT/CT with routine cross-sectional, sonographic and conventional radiographic imaging. **[ABSTRACT EDITED]**

## Journal Tables of Contents

The most recent issues of the following journals:

- The American Journal of Sports Medicine
- British Journal of Sports Medicine
- Journal of Acute Medicine
- Emergency Medicine Journal
- Spine

Click on the [journal title \(hyperlinked + Ctrl\)](#) for the most recent tables of contents. If you would like any of the papers in full text then please email the library: [library@uhbristol.nhs.uk](mailto:library@uhbristol.nhs.uk)

### The American Journal of Sports Medicine

June 2017, Volume 45, Issue 7

### British Journal of Sports Medicine

June 2017, Volume 51, Issue 12

### Emergency Medicine Journal

June 2017, Volume 34, Issue 6

### Spine

June 1 2017, Volume 42, Issue 11

## Exercise: Creating a search strategy

**Scenario:** A 64 year old obese male who has tried many ways to lose weight presents with a newspaper article about 'fat-blazer' (chitosan). He asks for your advice.

### 1. What would your PICO format be?

Population/problem	
Intervention/indicator	
Comparator	
Outcome	

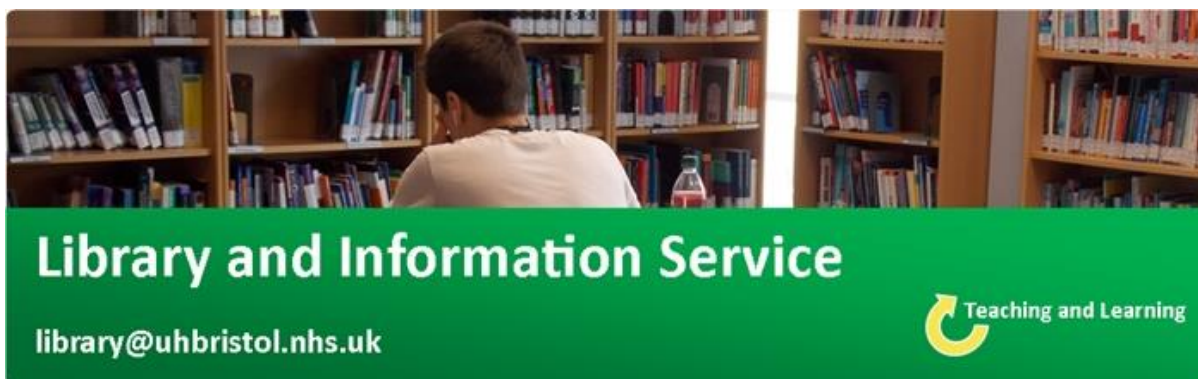### 2. What would your research question be?

*Taken from the Centre for Evidence Based Medicine*

*Find out more about constructing an effective search strategy in one of our **Literature searching** training sessions.*

*For more details, email [library@uhbristol.nhs.uk](mailto:library@uhbristol.nhs.uk).*

**PICO:** P = obese patients; I = chitosan; C = placebo; O = decrease weight  
**Research question:** In obese patients, does chitosan, compared to a placebo, decrease weight?



## Library Opening Times

**Staffed hours: 8am-5pm, Monday to Friday**

**Swipe-card access: 7am-11pm, seven days a week**

**Level 5, Education and Research Centre**

**University Hospitals Bristol**

**Contact your Outreach Librarian:**

**Jo Hooper**

**[library@uhbristol.nhs.uk](mailto:library@uhbristol.nhs.uk)**

**Ext. 20105**