

Restorative Dentistry

Current Awareness Newsletter
February-March 2017



Respecting everyone
Embracing change
Recognising success
Working together
Our hospitals.



Library and Information Service
library@uhbristol.nhs.uk 

Training Sessions 2017

All sessions are 1 hour

February (12.00)

Fri 3 rd	Literature Searching
Mon 6 th	Critical Appraisal
Tues 14 th	Statistics
Wed 22 nd	Literature Searching

March (1pm - 2pm)

Thurs 2 nd	Critical Appraisal
Fri 10 th	Interpreting Statistics
Mon 13 th	Literature Searching
Tues 21 st	Critical Appraisal
Weds 29 th	Interpreting Statistics



Your Outreach Librarian – Jo Hooper

Whatever your information needs, the library is here to help. We offer **literature searching services** as well as training and guidance in **searching the evidence** and **critical appraisal** – just email us at library@uhbristol.nhs.uk

Outreach: Your Outreach Librarian can help facilitate evidence-based practice for all in the restorative dentistry team, as well as assisting with academic study and research. We can help with **literature searching, obtaining journal articles and books**. We also offer one-to-one or small group training in **literature searching, accessing electronic journals, and critical appraisal**. Get in touch: library@uhbristol.nhs.uk

Literature searching: We provide a literature searching service for any library member. For those embarking on their own research it is advisable to book some time with one of the librarians for a 1 to 1 session where we can guide you through the process of creating a well-focused literature research and introduce you to the health databases access via NHS Evidence. Please email requests to library@uhbristol.nhs.uk

Contents

The Latest Evidence for Restorative Dentistry.....	4
NICE National Institute for Health and Care Excellence	4
	4
	5
 The Dental Elf	5
Current Awareness Database Articles on Restorative Dentistry	7
Peri-implantitis	7
Bisphosphonate-related osteonecrosis of the jaw	11
Dental-related cleft lip and palate.....	18
Periodontal disease and antibiotics.....	22
Dental-related head and neck oncology	26
Dental implants	31
Journal Tables of Contents.....	42
British Dental Journal.....	42
Evidence Based Dentistry.....	42
International Journal of Oral and Maxillofacial Implants.....	42
International Journal of Prosthodontics	42
Journal of Clinical Periodontology	42
Exercise: Outcome Reliability.....	43
Library Opening Times.....	44

The Latest Evidence for Restorative Dentistry

NICE National Institute for
Health and Care Excellence

[Clinical and Radiological Outcomes of Implants in Osteotome Sinus Floor Elevation with and without Grafting: A Systematic Review and a Meta-Analysis](#)

Source: [PubMed](#) - 12 January 2017 - Publisher: Journal Of Prosthodontics : Official Journal Of The American College Of Prosthodontists

[Read Summary](#)

- **More:** [Systematic Reviews](#)

[Palliative care - oral](#)

Source: [Clinical Knowledge Summaries - CKS](#) - 24 January 2017

[Read Summary](#)

- **More:** [Guidance](#)



[Non-pharmacological interventions for alleviating pain during orthodontic treatment](#)

Padhraig S Fleming, Hardus Strydom, Christos Katsaros, LCI MacDonald, Michele Curatolo,

Online Publication Date: December 2016

- Review
- Intervention

[Single versus multiple visits for endodontic treatment of permanent teeth](#)

Maddalena Manfredi, Lara Figini, Massimo Gagliani, Giovanni Lodi

Online Publication Date: December 2016

- New search
- Review
- Intervention

UpToDate®

OpenAthens login required. Register here: <https://openathens.nice.org.uk/>

[Medication-related osteonecrosis of the jaw in patients with cancer](#)

- [Prevention](#)
- [Summary and recommendations](#)

[Gingivitis and periodontitis in adults: Classification and dental treatment](#)

- [Peri-implantitis](#)
- [Summary](#)

[Mandibular and palatal reconstruction in patients with head and neck cancer](#)

- [Mandibular reconstruction](#)
- [Summary](#)
- [Bad breath](#)
- [Summary and recommendations](#)

[Risks of bisphosphonate therapy in patients with osteoporosis](#)

- [Osteonecrosis of the jaw](#)
- [Summary and recommendations](#)



The Dental Elf

[Dental Implant survival in patients with aggressive periodontitis](#)

Feb 10 2017 Posted by: [Derek Richards](#)

The aim of this review was to assess the outcomes of implant therapy in partially dentate patients treated for aggressive periodontitis (GAgP) in comparison to periodontally healthy (HP) and patients treated for chronic periodontitis (CP)

[Periodontal treatment: outcomes from long-term conservative management](#)

Feb 6 2017 Posted by: [Derek Richards](#)

The aim of this study were (i) to determine prognostic factors of tooth loss in a compliant cohort of patients under a conservative periodontal treatment concept and (ii) to describe long-term trajectories of bone loss (BL) and pocket probing depths (PPD).



UpToDate is the leading evidence-based clinical decision support system, designed for use at the point of care.

It contains more than 9,500 searchable topics across the following specialities:

- ❖ Adult and paediatric emergency medicine
- ❖ Allergy and immunology
- ❖ Cardiovascular medicine
- ❖ Dermatology
- ❖ Drug therapy
- ❖ Endocrinology and diabetes mellitus
- ❖ Family medicine
- ❖ Gastroenterology and hepatology
- ❖ General surgery
- ❖ Geriatrics
- ❖ Haematology
- ❖ Hospital Medicine
- ❖ Infectious diseases
- ❖ Nephrology and hypertension
- ❖ Neurology
- ❖ Obstetrics and gynaecology
- ❖ Oncology
- ❖ Paediatrics
- ❖ Primary care internal medicine
- ❖ Psychiatry
- ❖ Pulmonary, critical care and sleep medicine
- ❖ Rheumatology

How to access UpToDate

You can access UpToDate from any computer via www.uptodate.com.

Current Awareness Database Articles on Restorative Dentistry

Below is a selection of articles on restorative dentistry recently added to the healthcare databases, grouped in the following categories:

- Peri-implantitis
- Bisphosphonate-related osteonecrosis of the jaw
- Dental-related cleft lip and palate
- Periodontal disease and antibiotics
- Dental-related head and neck oncology
- Dental implants

If you would like any of the following articles in full text, or if you would like a more focused search on your own topic, then get in touch: library@uhbristol.nhs.uk

Peri-implantitis

A peri-implantitis associated with a pre-existing pathology.

Author(s): Oh, S E-L I M

Source: The Journal of oral implantology; Feb 2017

Publication Type(s): Journal Article

Abstract: This case report presents a treatment of peri-implantitis associated with a pre-existing pathology. Peri-implantitis around the implant #19 was detected from pus discharge upon probing. Guided bone regeneration was performed to treat peri-implantitis with the administration of antibiotics. The histopathologic evaluation of soft tissue taken from the circumferential defect around the implant exhibited a cyst. The post-surgical CBCT and the follow-up radiograph confirmed the maturing bone graft and a reduced size of the defect around the implant.

Microbial Characteristics of Peri-Implantitis: A Case-Control Study.

Author(s): de Waal, Y C; Eijsbouts, H V; Winkel, E G; van Winkelhoff, A J

Source: Journal of periodontology; Feb 2017; vol. 88 (no. 2); p. 209-217

Publication Type(s): Journal Article

Abstract: The aim of this case-control study is to compare oral microbiologic characteristics of patients with healthy peri-implant conditions and patients with peri-implantitis and to explore the influence of various patient- and implant-related factors on microbiologic characteristics. Peri-implant submucosal microbial samples were collected from 85 patients with peri-implantitis (cases) and from 69 patients with only implants with healthy peri-implant conditions (controls). Samples were analyzed using culturing techniques. Multivariable logistic regression was used to explore the association of disease status and various patient- and implant-related factors (sex, patient age, smoking, number of remaining teeth, percentage of teeth with bone loss, implant function time, implant surface, and presence of plaque) with microbiologic characteristics. Peri-implant disease status was significantly associated with the submucosal presence of *Porphyromonas gingivalis* (Pg), *Prevotella intermedia* (Pi), *Tannerella forsythia* (Tf), and *Fusobacterium nucleatum* (Fn). The

association with disease status was most obvious for Pi (odds ratio [OR]: 15.1; 95% confidence interval [CI]: 5.1 to 45.3) and Tf (OR: 13.3; 95% CI: 5.4 to 32.5). The prevalence of *Aggregatibacter actinomycetemcomitans* and *Staphylococcus* species was very low. The periodontal pathogens Pg, Pi, Tf, and Fn are associated with peri-implantitis. *A. actinomycetemcomitans* and *Staphylococcus* species do not seem to play an important role in peri-implantitis.

Risk indicators for Peri-implantitis. A cross-sectional study with 916 implants.

Author(s): Dalago, Haline Renata; Schuldt Filho, Guenther; Rodrigues, Mônica Abreu Pessoa; Renvert, Stefan; Bianchini, Marco Aurélio

Source: Clinical oral implants research; Feb 2017; vol. 28 (no. 2); p. 144-150

Publication Type(s): Journal Article

Abstract:OBJECTIVES The aim of this study was to identify systemic and local risk indicators associated with peri-implantitis. MATERIAL AND METHODS One hundred eighty-three patients treated with 916 osseointegrated titanium implants, in function for at least 1 year, were included in the present study. The implants were installed at the Foundation for Scientific and Technological Development of Dentistry (FUNDECTO) - University of Sao Paulo (USP) - from 1998 to 2012. Factors related to patient's systemic conditions (heart disorders, hypertension, smoking habits, alcoholism, liver disorders, hepatitis, gastrointestinal disease, diabetes mellitus I and II, hyperthyroidism or hypothyroidism, radiation therapy, chemotherapy, menopause, osteoporosis, active periodontal disease, history of periodontal disease and bruxism), implant's characteristics (location, diameter, length, connection, shape, and antagonist), and clinical parameters (wear facets, periodontal status on the adjacent tooth, plaque accumulation on the adjacent tooth, modified plaque index, sulcus bleeding index, probing depth, bleeding on probing, width of keratinized tissue and marginal recession). RESULTS An increased risk of 2.2 times for history of periodontal disease (PD), 3.6 times for cemented restorations compared to screw-retained prostheses, 2.4 times when wear facets were displayed on the prosthetic crown and 16.1 times for total rehabilitations when compared to single rehabilitations were found. Logistic regression analysis did not show any association between the implant's characteristics and peri-implantitis. CONCLUSIONS A history of periodontal disease, cemented prostheses, presences of wear facets on the prosthetic crown and full mouth rehabilitations were identified as risk indicators for peri-implantitis. Implants' characteristics were not related to the presence of peri-implantitis.

Occlusal trauma and mucositis or peri-implantitis?

Author(s): Passanezi, Euloir; Passanezi Sant'Ana, Adriana Campos; Damante, Carla Andreotti

Source: Journal of the American Dental Association (JADA); Feb 2017; vol. 148 (no. 2); p. 106-112

Publication Type(s): Academic Journal

Treatment of peri-implantitis: clinical outcome of chloramine as an adjunctive to non-surgical therapy, a randomized clinical trial.

Author(s): Roos-Jansåker, Ann-Marie; Almhöjd, Ulrica S; Jansson, Henrik

Source: Clinical oral implants research; Jan 2017; vol. 28 (no. 1); p. 43-48

Publication Type(s): Journal Article

Abstract:To evaluate the adjunctive clinical effects of a chloramine to non-surgical treatment of peri-implantitis. Eighteen individuals diagnosed with peri-implantitis (clinical signs of inflammation

and progressive bone loss) on at least two implants were included. Clinical variables; plaque accumulation (PI), probing depth (PD), clinical attachment level (CAL) and bleeding on probing (BoP), were recorded at baseline and at 3-month follow-up. Primary clinical efficacy variable was the change in the number of sites with BoP. The implants were randomized into two different treatment groups: test and control. Both implants received supra- and submucosal debridement by ultrasonic instrumentation supplemented with hand instruments. The implants assigned to the test group first received local applications of a chloramine gel (Perisolv™; RLS Global AB, Gothenburg, Sweden) followed by mechanical instrumentation. The oral hygiene was checked at 6 weeks. After 3 months, implants of both groups showed statistically significant reduction ($P < 0.001$) in the number of BoP-positive sites compared with baseline. The reduction of BoP-positive sites in the test group changed from 0.97 (SD \pm 0.12) to 0.38 (SD \pm 0.46), and in the control group from 0.97 (SD \pm 0.12) to 0.31 (SD \pm 0.42). Between-group comparisons revealed no statistically significant differences at baseline and after 3 months, for BoP or any of the other variables. In the present randomized clinical trial of peri-implantitis therapy; non-surgical mechanical debridement with adjunctive use of a chloramine is equally effective in the reduction of mucosal inflammation as conventional non-surgical mechanical debridement up to 3 months. © 2015 John Wiley & Sons A/S. Published by John Wiley & Sons Ltd.

An immediate peri-implantitis induction model to study regenerative peri-implantitis treatments.

Author(s): Park, Shin-Young; Kim, Kyoung-Hwa; Rhee, Sang-Hoon; Lee, Jeong-Cheol; Shin, Seung-Yun; Lee, Yong-Moo; Seol, Yang-Jo

Source: Clinical oral implants research; Jan 2017; vol. 28 (no. 1); p. 36-42

Publication Type(s): Journal Article

Abstract: The aim of this study was to evaluate the validity of the immediate peri-implantitis model to test regenerative therapies in peri-implantitis defects. In an immediate peri-implantitis model in beagles, the mandibular third premolars were extracted, and dental implants were immediately placed in the distal extraction sockets. Without a healing period, experimental peri-implantitis was induced by ligature placement for 3 months. In the conventional peri-implantitis model, dental implants were placed in the healed mandibular fourth premolar region and were submerged for osseointegration. After 3 months of healing, peri-implantitis induction was performed for another 3 months. After peri-implantitis defects were formed in both models, regenerative therapy was performed in both models. After 3 months in the immediate model and 9 months in the conventional model, similarly shaped horizontal bone defects (wide and craterlike) were observed. However, buccal bone defects were deeply formed in the immediate model compared with the conventional model (6.02 ± 1.20 and 4.34 ± 0.86 mm, respectively; $P = 0.009$), but the amounts of bone regeneration were not significantly different between the models ($P = 0.107$). On the lingual side, re-osseointegration was significantly greater in the conventional model than in the immediate model (0.72 ± 0.50 and 1.77 ± 0.87 mm, respectively; $P = 0.009$), although lingual bone defects were not significantly different between the models ($P = 0.248$). Although the immediate peri-implantitis model is challenging for regeneration, it may be able to replace the conventional model to study regenerative peri-implantitis treatment due to its short experimental time and similar defect configuration. © 2015 John Wiley & Sons A/S. Published by John Wiley & Sons Ltd.

Clinical, Radiographic and Microbiological Evaluation of High Level Laser Therapy, a New Photodynamic Therapy Protocol, in Peri-Implantitis Treatment; A Pilot Experience

Author(s): Caccianiga G.; Baldoni M.; Paiusco A.; Rey G.

Source: BioMed Research International; 2016; vol. 2016

Publication Type(s): Journal: Article

Available in full text at [BioMed Research International](#) - from ProQuest

Abstract: Aim. Endosseous implants are widely used to replace missing teeth but mucositis and peri-implantitis are the most frequent long-term complications related with dental implants. Removing all bacterial deposits on contaminated implant surface is very difficult due to implant surface morphology. The aim of this study was to evaluate the bactericidal potential of photodynamic therapy by using a new high level laser irradiation protocol associated with hydrogen peroxide in peri-implantitis. **Materials and Methods.** 10 patients affected by peri-implantitis were selected for this study. Medical history, photographic documentation, periodontal examination, and periapical radiographs were collected at baseline and 6 months after surgery. Microbiological analysis was performed with PCR Real Time. Each patient underwent nonsurgical periodontal therapy and surgery combined with photodynamic therapy according to High Level Laser Therapy protocol. **Results.** All peri-implant pockets were treated successfully, without having any complication and not showing significant differences in results. All clinical parameters showed an improvement, with a decrease of Plaque Index (average decrease of 65%, range 23-86%), bleeding on probing (average decrease of 66%, range 26-80%), and probing depth (average decrease of 1,6 mm, range 0,46-2,6 mm). Periapical radiographs at 6 months after surgery showed a complete radiographic filling of peri-implant defect around implants treated. Results showed a decrease of total bacterial count and of all bacterial species, except for *Eikenella corrodens*, 6 months after surgery. **Conclusion.** Photodynamic therapy using HLLT appears to be a good adjunct to surgical treatment of peri-implantitis. Copyright © 2016 Gianluigi Caccianiga et al.

Natural resistance associated macrophage protein 1 gene polymorphism is associated with chronic periodontitis not peri-implantitis in an Iranian population: A cross sectional study

Author(s): Kadkhodazadeh M.; Ebadian A.R.; Amid R.; Zarnegarnia P.; Aghamohammadi N.; Mollaverdi F.

Source: Acta Medica Iranica; 2016; vol. 54 (no. 5); p. 323-329

Publication Type(s): Journal: Article

Available in full text at [Acta Medica Iranica](#) - from ProQuest

Abstract: In inflammatory diseases such as peri-implantitis (PI) and chronic periodontitis (CP) both adaptive and innate immunity play a part. Natural resistance associated macrophage protein 1 (NRAMP1) has considerable effects on macrophage function (phagocytosis) and host innate immune response against infections. The present study was to investigate the relationship of NRAMP1 gene polymorphisms with PI and CP in an Iranian population. In this cross sectional study 79 patients with CP, 38 patients with PI and 84 healthy controls presenting to the Periodontology Department of Shahid Beheshti University of Medical Sciences were enrolled. DNA was extracted from fresh blood samples of arm vein of participants and transferred to KBioscience institute (United Kingdom) for genotyping. X2 and Fisher's exact tests were used by SPSS software v.19 for statistical analyzes. Significant differences were detected in the distribution of genotypes between control and CP groups both for rs17235409 and rs2276631 polymorphisms (P:0.044 and P:0.028 respectively). Distribution of genotypes differed insignificantly in comparison of PI and control groups for rs2276631 (P:0.623) and either rs17235409 (P:1) polymorphisms. Based on our results, we conclude that presence of G allele in both rs2276631 and rs17235409 location may be a protective factor against CP. More studies with a larger sample size in different populations are required for confirming NRAMP1 as a genetic determinant in periodontal disorders. Copyright © 2016 Tehran University of Medical Sciences. All rights reserved.

Bisphosphonate-related osteonecrosis of the jaw

Quantitative real-time gene profiling of human alveolar osteoblasts

Author(s): Coates D.E.; Zafar S.; Milne T.J.

Publication Type(s): Book Series: Chapter

Abstract:The use of quantitative real-time reverse transcriptase PCR (qRT2-PCR) for the identification of differentially regulated genes is a powerful technology. The protocol presented here uses qRT2-PCR gene arrays to investigate the regulation of 84 angiogenic related genes in human primary alveolar osteoblasts following treatment with the bisphosphonate, zoledronic acid (ZA), and geranylgeraniol (GGOH). GGOH has potential as a therapeutic agent for Bisphosphate-Related Osteonecrosis of the Jaw (BRONJ), a serious side-effect resulting from the treatment for metastatic cancer (Zafar et al., J Oral Pathol Med 43:711-721, 2014; Ruggiero, Ann NY Acad Sci 1218:38-46, 2011). The isolation of the primary osteoblast cells follows the methods previously described (Dillon et al., Methods Mol Biol 816:3-18, 2012) with a new RNA extraction technique described fully. The method highlights the importance of obtaining high-quality RNA which is DNA-free. Relative levels of gene expression are normalized against selected housekeeping genes (HKG) and a number of examples of how fold regulation (2-DELTADELTA Cq) and gene expression level (2-DELTA Cq) data can be presented are given. Copyright © Springer Science+Business Media LLC 2017.

Efficacy of the C-terminal telopeptide test in predicting the development of bisphosphonate-related osteonecrosis of the jaw: a systematic review

Author(s): Dal Pra K.J.; Soubhia A.M.P.; Lemos C.A.A.; Pellizzer E.P.; Okamoto R.

Source: International Journal of Oral and Maxillofacial Surgery; Feb 2017; vol. 46 (no. 2); p. 151-156

Publication Type(s): Journal: Review

Abstract:This systematic review evaluated the efficacy of the morning fasting serum C-terminal telopeptide (CTX) test in predicting the development of bisphosphonate-related osteonecrosis of the jaw (BRONJ). A comprehensive search of studies published up to March 2016, and listed in the PubMed/MEDLINE, Web of Science, and Cochrane Library databases, was performed in accordance with the Preferred Reporting Items for Systematic Reviews and Meta-Analyses (PRISMA) guidelines. This review has been registered in the PROSPERO international prospective register of systematic reviews (CRD42016036717). The search identified 542 publications; eight studies were finally deemed eligible for inclusion according to the study criteria. These studies included a total 1442 patients (mean age 66.7 years). The most prescribed drug was alendronate, with osteoporosis being the most frequent indication for the prescription of bisphosphonates. Tooth extraction was the most common trigger for BRONJ. Of all patients evaluated after bisphosphonate treatment, only 24 (1.7%) developed BRONJ. All eight of the selected studies found that CTX levels were not predictive of the development of BRONJ. In conclusion, this systematic review indicates that the CTX test has no predictive value in determining the risk of osteonecrosis in patients taking bisphosphonates. Copyright © 2016 International Association of Oral and Maxillofacial Surgeons

Histochemical observation of bony reversal lines in bisphosphonate-related osteonecrosis of the jaw.

Author(s): Kim, Soung Min; Eo, Mi Young; Kim, Yeon Sook; Lee, Suk Keun

Source: Oral surgery, oral medicine, oral pathology and oral radiology; Feb 2017; vol. 123 (no. 2); p. 220-228

Publication Type(s): Journal Article

Abstract: To contrast the pattern of bony reversal lines in bisphosphonate osteonecrosis of the jaw with infected osteomyelitis derived acute osteonecrosis of the jaw. This study investigated the histochemical characteristics of reversal lines in 50 cases of BP-related osteonecrosis of the jaw (BRONJ) compared with non-BP-involved bones in 20 cases of chronic osteomyelitis of the jaws. Necrotic bones were stained by using the toluidine blue, Safranin O, Giemsa, van Gieson, and Masson's trichrome staining methods. All BP-involved bones in BRONJ were distinguishable from non-BP-involved bones in chronic osteomyelitis of the jaws by multiple thick, irregular, reversal lines, which were strongly stained with toluidine blue, Safranin O, and Giemsa solution. The reversal lines of BP-involved bones (average $31.2 \pm 10.85 \mu\text{m}$) were thicker than those of osteomyelitic bones (average $11.1 \pm 3.76 \mu\text{m}$), and they were closely associated with immature bony matrices containing collagenous materials positive for van Gieson and Masson's trichrome staining with statistical significance ($P = .0212$ in t test statistics). The immature reversal lines of BP-involved bones continuously appeared as thick non-birefringence lines between lamellate structures as observed under a polarizing microscope, whereas the reversal lines of non-BP-involved bones were gradually thinned as their mineralization advanced. BP-involved bones had immature bony matrices outlined by thick reversal lines, which might be crucial to rapid osteonecrosis of BRONJ and also could be hallmarks for the differential diagnosis of BRONJ from chronic osteomyelitis of the jaws. Copyright © 2016 Elsevier Inc. All rights reserved.

IL-36 Induces Bisphosphonate-Related Osteonecrosis of the Jaw-Like Lesions in Mice by Inhibiting TGF- β -Mediated Collagen Expression.

Author(s): Kim, Sol; Williams, Drake W; Lee, Cindy; Kim, Teresa; Arai, Atsushi; Shi, Songtao; Li, Xinmin; Shin, Ki-Hyuk; Kang, Mo K; Park, No-Hee; Kim, Reuben H

Source: Journal of bone and mineral research : the official journal of the American Society for Bone and Mineral Research; Feb 2017; vol. 32 (no. 2); p. 309-318

Publication Type(s): Journal Article

Abstract: Long-term administration of nitrogen-containing bisphosphonates can induce detrimental side effects such as bisphosphonate-related osteonecrosis of the jaw (BRONJ) in human. Although inflammation is known to be associated with BRONJ development, the detailed underlying mechanism remains unknown. Here, we report that the pro-inflammatory cytokine IL-36 α is, in part, responsible for the BRONJ development. We found a notably higher level of IL-36 α and lower level of collagen in the BRONJ lesions in mice. We also found that IL-36 α remarkably suppressed TGF- β -mediated expression of Coll α 1 and α -Sma via the activation of Erk signaling pathway in mouse gingival mesenchymal stem cells. When IL-36 signaling was abrogated in vivo, development of BRONJ lesions was ameliorated in mice. Taken together, we showed the pathologic role of IL-36 α in BRONJ development by inhibiting collagen expression and demonstrated that IL-36 α could be a potential marker and a therapeutic target for the prevention and treatment of BRONJ. © 2016 American Society for Bone and Mineral Research. © 2016 American Society for Bone and Mineral Research.

Dental extraction following zoledronate, induces osteonecrosis in rat's jaw.

Author(s): Vidal-Gutiérrez, X; Gómez-Clavel, J-F; Gaitán-Cepeda, L-A

Source: Medicina oral, patologia oral y cirugia bucal; Feb 2017 ; p. 0

Publication Type(s): Journal Article

Abstract:BACKGROUND Bisphosphonate-Related Osteonecrosis of the Jaw (BRONJ) is clinically characterized by the presence of exposed bone in the oral cavity that persists for more than eight weeks. Previous attempts to establish an animal model have not sufficiently considered disease features. Our aim was to establish an inexpensive and replicable animal model that develops BRONJ in a short time. MATERIAL AND METHODS Thirty-two male Wistar rats were randomly divided into two groups: control and experimental. In the experimental group, we administered 0.06mg/kg intraperitoneal dose of zoledronic acid (ZA) 7 and 14 days prior to maxillary second molar extraction. At two, four and six weeks after tooth extraction, the animals were euthanized, and we dissected the maxilla following histological procedures. We stained serial slides with hematoxylin and eosin and Masson's trichrome. The samples were harvested for macroscopic, radiologic and histological evaluation of bone changes. RESULTS At two weeks postextraction, we observed exposed necrotic bone in dental socket areas in experimental groups. Radiological analysis revealed osteolytic lesions accompanied by extensive destruction and sequestrum formation in the same group. Histological examination confirmed the absence of necrotic bone in control groups in contrast with the experimental groups. The percentage of empty lacunae and the number of osteoclasts and the necrotic bone area were significantly increased ($p < 0.05$) in the experimental groups. CONCLUSIONS The animal model using ZA administration to prior dental extraction successfully mimicked human BRONJ lesions. Also, the model was easily replicated, inexpensive and showed different features than other previous BRONJ models.

Consultation with a specialized pain clinic reduces pain after oral and maxillofacial surgery.

Author(s): Dietrich, Eva-Maria; Griessinger, Norbert; Neukam, Friedrich Wilhelm; Schlittenbauer, Tilo

Source: Journal of cranio-maxillo-facial surgery : official publication of the European Association for Cranio-Maxillo-Facial Surgery; Feb 2017; vol. 45 (no. 2); p. 281-289

Publication Type(s): Journal Article

Abstract:PURPOSE Postoperative pain management is important for improved patient care. Our primary objective was to investigate the effect of analgesic treatment adaptation by the pain clinic on postoperative pain relief at an oral and maxillofacial surgery department. Additionally, we aimed to present patients' pain characteristics and the administered analgesic treatment. MATERIALS AND METHODS A total of 128 patients treated at our clinic in the period 2012-2015 who required analgesic treatment adaptation by our pain clinic were included. They were further divided into 10 groups: tumor, temporomandibular joint disorder, tooth extraction, osteomyelitis, bisphosphonate-related osteonecrosis of the jaw, submandibular abscess, orthognathic surgery, cyst, sinusitis, and fracture. Pain characteristics evaluated were intensity on a numerical rating scale (NRS) before and after intervention of the pain clinic, quality, genesis, and type. RESULTS Post treatment pain intensity values at rest 1.8 (SD: 1.4) and on exercise (walking and physical therapy) 4 (SD: 2) were statistically significant better compared to pretreatment values (4.2, SD: 2.5, and 6.8 SD: 2, respectively). The highest pain intensities were reported after tooth extractions, orthognathic surgery, cystectomies, and fracture reposition. Pain was mainly continuous and related to a combination of a somatic and a neuropathic pathophysiological mechanism. CONCLUSIONS Intervention by a specialized pain clinic leads to reduction of postoperative pain.

PP - ONE YEAR FOLLOW-UP OF CONSERVATIVE MANAGEMENT OF STAGE 3 BISPHOSPHONATE-RELATED OSTEONECROSIS OF THE JAW (BRONJ).

Author(s): CALDAS, ROGÉRIO JARDIM; RUBIRA, CÁSSIA MARIA FISCHER; DA SILVA SANTOS, PAULO SÉRGIO

Source: Oral Surgery, Oral Medicine, Oral Pathology & Oral Radiology; Feb 2017; vol. 123 (no. 2)

Publication Type(s): Academic Journal

Risk of Jaw Osteonecrosis After Intravenous Bisphosphonates in Cancer Patients and Patients Without Cancer

Author(s): Goodwin J.S.; Kuo Y.-F.; Zhou J.; Baillargeon J.

Source: Mayo Clinic Proceedings; Jan 2017; vol. 92 (no. 1); p. 106-113

Publication Type(s): Journal: Article

Available in full text at [Mayo Clinic Proceedings](#) - from ProQuest

Abstract:Objective To compare the risk of jaw osteonecrosis after intravenous (IV) bisphosphonate administered to patients with cancer vs patients without cancer. Patients and Methods We conducted a retrospective cohort study of a 5% national sample of Medicare patients administered IV bisphosphonate from January 1, 2008, through December 31, 2013, for cancer vs noncancer indications. Probable jaw osteonecrosis was estimated with an algorithm including diagnoses, surgical procedures, and imaging studies. A non-IV bisphosphonate comparison group included patients prescribed an oral bisphosphonate for 30 days or less. Results During follow-up, 40 (0.42%) out of 9482 patients with cancer developed probable jaw osteonecrosis compared with 8 (0.05%) out of 16,046 patients without cancer. In a Cox multivariable survival analysis controlling for patient characteristics and number of IV zoledronic infusions, patients without cancer had a hazard ratio of 0.17 (95% CI, 0.06-0.46) for developing jaw osteonecrosis compared with those with cancer. The lower rate of jaw osteonecrosis in patients without cancer was also confirmed in a number of sensitivity analyses. Conclusion The low rate of jaw osteonecrosis in patients with osteoporosis who receive IV bisphosphonate should be weighed against the benefit of those agents in preventing hip and other fractures. Copyright © 2016 Mayo Foundation for Medical Education and Research

10. The starting point for bisphosphonate-related osteonecrosis of the jaw: Alveolar bone or oral mucosa? A randomized, controlled experimental study

Author(s): Zandi M.; Janbaz P.; Malekzadeh H.; Dehghan A.; Amini P.

Source: Journal of Cranio-Maxillofacial Surgery; Jan 2017; vol. 45 (no. 1); p. 157-161

Publication Type(s): Journal: Article

Abstract:Objective Although over a decade has passed since first introduction of BRONJ, the exact pathophysiology of this disease is still unclear. The present experimental study aimed to determine whether the oral mucosa or alveolar bone serves as the starting point for BRONJ development. Subjects and methods Sixty male Wistar rats were randomly assigned into study and control groups (each, n = 30), and received intraperitoneal injection of 0.06 mg/kg zoledronate and saline, respectively, once a week for 12 weeks. At the end of the week 4 of the experiment, all 60 rats underwent unilateral mandibular first molar extraction. A 4 mm defect was made in the contralateral canine alveolar mucosa. At the end of the experiment, rats were sacrificed, and the three areas of interest including extraction, soft tissue defect, and the non-intervention (canine area on the same side of extraction) sites were assessed clinically for presence of bone exposure/fistula, and histologically for status of bone remodeling (only at extraction site) and osteonecrosis. Results In the study group, the frequency of bone exposure/fistula was 80%, 0%, and 0%; and the rate of histological bone necrosis was 83.3%, 20%, and 0%; at the extraction, soft tissue defect, and non-

intervention sites, respectively. No clinical and histological sign of bone necrosis was found in the control group. Normal bone remodeling was observed in 0% and 100% of the extraction sockets in the study and control groups, respectively. Conclusion Injury to alveolar bone was a stronger trigger for BRONJ development compared to oral mucosal damages. Copyright © 2016 European Association for Cranio-Maxillo-Facial Surgery

Bone-site-specific responses to zoledronic acid

Author(s): Vermeer J.A.F.; Renders G.A.P.; van Duin M.A.; Bakker L.F.; Kroon S.A.; Everts V.; Jansen I.D.C.; de Vries T.J.

Source: Oral Diseases; Jan 2017; vol. 23 (no. 1); p. 126-133

Publication Type(s): Journal: Article

Abstract: Objectives: Bisphosphonates are widely used to treat bone diseases such as osteoporosis. However, they may cause osteonecrosis of the jaw. Here, we investigated whether in vivo exposure to bisphosphonates has a different effect on long bone and jaw osteoclasts, and on the turnover of these different bones. Materials and Methods: Zoledronic acid (0.5 mg kg⁻¹ weekly) was administered intraperitoneally to 3-month-old female mice for up to 6 months. The effects on the number of osteoclasts, bone mineralization and bone formation were measured in the long bones and in the jaw. Results: Long-term treatment with zoledronic acid reduced the number of jaw bone marrow cells, without affecting the number of long bone marrow cells. Zoledronic acid treatment did not affect the number of osteoclasts in vivo. Yet, the bisphosphonate increased bone volume and mineral density of both long bone and jaw. Interestingly, 6 months of treatment suppressed bone formation in the long bones without affecting the jaw. Unexpectedly, we showed that bisphosphonates can cause molar root resorption, mediated by active osteoclasts. Conclusions: Our findings provide more insight into bone-site-specific effects of bisphosphonates and into the aetiology of osteonecrosis of the jaw. We demonstrated that bisphosphonates can stimulate osteoclast activity at the molar roots. Copyright © 2016 John Wiley & Sons A/S. Published by John Wiley & Sons Ltd

Prophylaxis and antibiotic therapy in management protocols of patients treated with oral and intravenous bisphosphonates.

Author(s): Bermúdez-Bejarano, Elena-Beatriz; Serrera-Figallo, María-Ángeles; Gutiérrez-Corrales, Aida; Romero-Ruiz, Manuel-María; Castillo-de-Oyagüe, Raquel; Gutiérrez-Pérez, José-Luis; Torres-Lagares, Daniel

Source: Journal of clinical and experimental dentistry; Jan 2017; vol. 9 (no. 1); p. e141

Publication Type(s): Journal Article Review

Abstract: INTRODUCTION Osteonecrosis of the jaw (MRONJ) linked to bisphosphonate treatment has specific characteristics that render its therapeutic management challenging for clinicians. Poor response to standard treatment makes it essential to take special precautions when treating this type of disease; therefore, antibiotic prophylaxis and/or antibiotic therapy have been proposed as effective and helpful tools in these situations. OBJECTIVES This article seeks to assess published evidence in order to evaluate the different protocols used for antibiotic prophylaxis and/or antibiotic therapy in the general context of patients treated with bisphosphonates. MATERIAL AND METHODS A literature review of the last 10 years was carried out in PubMed using the following keywords: "antibiotic prophylaxis and osteonecrosis," "bisphosphonates AND osteonecrosis AND dental management," "bisphosphonate AND osteonecrosis AND antibiotic prophylaxis AND oral surgery." A total of 188 articles were obtained, of which 18 were ultimately selected. RESULTS AND DISCUSSION

In patients treated with oral and intravenous bisphosphonates without chemotherapy-associated osteonecrosis of the jaw, antibiotic prophylaxis prior to oral surgery is an important tool to avoid osteonecrosis and promote healing of the affected area. If the patient previously exhibited chemotherapy-associated osteonecrosis after tooth extraction, antibiotic prophylaxis is indicated to prevent recurrent osteonecrosis and promote healing of the extraction site. If chemotherapy-associated osteonecrosis is already present, antibiotic therapy is a vital part of conservative management to reduce the symptomatology of MRONJ and keep it from worsening. Finally, a lack of clinical data and randomized controlled trials makes it difficult to choose the most appropriate protocol for the various clinical situations studied. Key words: Bisphosphonates, antibiotic prophylaxis, maxillary osteonecrosis, antibiotic treatment.

Differential modulation of zoledronate and etidronate in osseous healing of an extracted socket and tibia defect.

Author(s): Lim, Shin Saeng; Lee, Beomseok; Kim, In Sook; Hwang, Soon Jung

Source: Oral surgery, oral medicine, oral pathology and oral radiology; Jan 2017; vol. 123 (no. 1); p. 8-19

Publication Type(s): Journal Article

Abstract: Osteonecrosis of the jaw has been increasing after dentoalveolar surgery in patients treated with an antiresorptive bisphosphonate (BP), especially strong zoledronate (ZA). The pathophysiology underlying why osteonecrosis occurs exclusively in the jaw bone remains unclear. This study investigated skeletal site-specific bone healing during the use of BPs to explore the preferential incidence of osteonecrosis of the jaw bone. Extraction of mandibular molar and creation of a tibia defect were performed in rats 2 weeks after weekly intravenous injections with the potent ZA and the weaker BP etidronate. Bone healing was evaluated radiographically and histologically 1 and 4 weeks after defect creation. Bone healing at the extracted socket showed that resorption precedes bone formation, while it was the opposite at the tibia defect. ZA use potentially suppressed bone remodeling, which led to impaired healing at the extracted socket but full regeneration of the tibia defect. However, etidronate showed less suppression of bone remodeling and resulted in increased bone formation at the extracted socket and full regeneration of the tibia defect. These results suggest that skeletal site-dependent differences in the bone healing process underlie BP-related preferential occurrence of osteonecrosis of the jaw bone. Copyright © 2016 Elsevier Inc. All rights reserved.

Effect of hyperbaric oxygen therapy on tooth extraction sites in rats subjected to bisphosphonate therapy-histomorphometric and immunohistochemical analysis.

Author(s): Silva, Miguel Luciano; Tasso, Leandro; Azambuja, Alan Arrieira; Figueiredo, Maria Antonia; Salum, Fernanda Gonçalves; da Silva, Vinicius Duval; Cherubini, Karen

Source: Clinical oral investigations; Jan 2017; vol. 21 (no. 1); p. 199-210

Publication Date: Jan 2017

Publication Type(s): Journal Article

Abstract: This study aimed to investigate the effect of hyperbaric oxygen therapy (HBOT) on tooth extraction sites in rats treated with bisphosphonate. Rats were treated with zoledronic acid, subjected to tooth extractions and allocated into groups: (1) 7 days of HBOT, (2) 14 days of HBOT, (3) 7-day control, and (4) 14-day control. The site of tooth extractions was analyzed by histomorphometry and immunohistochemistry. On macroscopic analysis, HBOT did not significantly

affect bone exposure volume either at 7 or 14 days. On hematoxylin and eosin (H&E) analysis, the 14-day HBOT group showed less non-vital bone compared to both controls and 7-day HBOT group. HBOT significantly lowered expression of vascular endothelial growth factor (VEGF), receptor activator NF- κ B ligand (RANKL), bone morphogenetic protein-2 (BMP-2), and osteoprotegerin (OPG) at 7 days, compared to control, whereas at 14 days, there was no significant difference for these variables. HBOT can reduce the amounts of non-vital bone microscopically detected in tooth extraction sites of rats subjected to bisphosphonate therapy. The effect seems to occur in a dose-dependent mode. Further studies are required to clarify the mechanisms accounting for this effect. Treatment of bisphosphonate-related osteonecrosis of the jaw (BRONJ) has been a challenging task, where the effectiveness of HBOT is controversial. This study reports important effects of HBOT on the maxillae of rats subjected to bisphosphonate treatment, making an important contribution to the knowledge about the applicability of HBOT in BRONJ.

Interrelationship of clinical, radiographic and hematological features in patients under bisphosphonate therapy.

Author(s): Koth, Valesca Sander; Figueiredo, Maria Antonia; Salum, Fernanda Gonçalves; Cherubini, Karen

Source: Dento maxillo facial radiology; Jan 2017 ; p. 20160260

Publication Type(s): Journal Article

Abstract: To analyze clinical, radiographic and hematological aspects of patients under bisphosphonate therapy. A retrospective study was conducted where the records of patients taking bisphosphonates were analyzed considering the occurrence of bisphosphonate-related osteonecrosis of the jaw (BRONJ). Evaluation included panoramic and periapical radiographies, hematological exams and clinical features. Radiographies were analyzed determining the presence or absence of bone sclerosis, osteolysis, persisting alveolar socket, narrowing of the mandibular canal, widening of the periodontal ligament space, periradicular radiolucency, sequestrum, and thickening of the lamina dura. Laboratory tests consisted of complete blood count (CBC), fasting serum glucose, erythrocyte sedimentation rate (ESR), and serum levels of calcium, phosphorus, alkaline phosphatase, parathormone (PTH) and C-terminal-telopeptide of collagen I (CTX). Alkaline phosphatase and erythrocyte sedimentation rate (ESR) were significantly higher in the BRONJ group, whereas fasting serum glucose, CTX, PTH, calcium and phosphorus did not significantly differ. BRONJ showed association with smoking, tooth extraction, anemia and leukocytosis. On radiographic analysis, persisting alveolar socket, osteolysis, bone sclerosis and narrowing of the mandibular canal were significantly more prevalent in the BRONJ group. Thickening of the lamina dura, periapical radiolucencies, widening of the periodontal ligament space and sequestrum did not significantly differ between the groups. BRONJ is a multifactorial disease with high morbidity, which requires experimental studies to clarify the role of the reported risk factors and clinical-radiographic signs to improve its diagnosis.

Skeletal Site-specific Effects of Zoledronate on in vivo Bone Remodeling and in vitro BMSCs Osteogenic Activity.

Author(s): Gong, Xue; Yu, Wanlu; Zhao, Hang; Su, Jiansheng; Sheng, Qing

Source: Scientific reports; Jan 2017; vol. 7 ; p. 36129

Publication Type(s): Journal Article

Abstract: Bisphosphonate-related osteonecrosis of the jaw (BRONJ) has been associated with long-term oral or intravenous administration of nitrogen-containing bisphosphonates (BPs). However, the

pathogenesis of BRONJ remains unknown, and definitively effective treatment has not yet been established. Bisphosphonate-related osteonecrosis (BRON) tends to occur in maxillofacial bones. Why this occurs is still unclear. Here we show that zoledronate (Zol) treatment suppresses alveolar bone remodeling after tooth typical clinical and radiographic hallmarks of the human BRONJ, whereas enhances peripheral bone quantity in bone remodeling following injury in the same individuals, shown as increased cortical bone thickness, increased trabecular bone formation and accelerated bone defect repair. We find that the RANKL/OPG ratio and Wnt-3a expression are suppressed at the extracted alveolar sites in Zol-treated rats compared with those at the injured sites of peripheral bones. We also show that Zol-treated bone marrow stromal cell (BMSCs) derived from jaw and peripheral bones exhibit differences in cell proliferation, alkaline phosphatase (ALP) activity, expression of osteogenic and chondrogenic related marker genes, and in vivo bone formation capacity. Hopefully, this study will help us better understand the pathogenesis of BRONJ, and deepen the theoretical research.

Dental-related cleft lip and palate

Blepharocheilodontic (BCD) syndrome: New insights on craniofacial and dental features.

Author(s): Awadh, Wael; Kiukkonen, Anu; Nieminen, Pekka; Arte, Sirpa; Hurmerinta, Kirsti; Rice, David P

Source: American journal of medical genetics. Part A; Feb 2017

Publication Type(s): Journal Article

Abstract: Blepharocheilodontic (BCD) syndrome is a rare condition characterized by bilateral cleft lip and palate (BCLP), eyelid abnormalities, and oligodontia. Despite orofacial clefting and oligodontia being central features of the condition, detailed reports of dental and craniofacial characteristics are scarce. The aim of this study was to analyze the dental and craniofacial features in a group of patients with BCD syndrome (three of which were related). Cephalometric radiographic analyses were performed on BCD syndrome patients (all radiographs taken at age 8 years) and compared to 40 randomly selected age-matched controls (20 non-syndromic BCLP, 20 non-cleft). Also, we assessed clinical records, photographs, dental study casts, and dental radiographs to determine the extent and pattern of tooth agenesis, dental morphology and malocclusion. BCD syndrome patients showed a very severe skeletal III malocclusion (maxillary-mandibular sagittal discrepancy) and reduced anterior lower face measurement compared to non-syndromic BCLP and non-cleft controls ($P = 0.001$, $P = 0.027$). All patients exhibited oligodontia (mean number of missing permanent teeth 13.7, range 7-17). All patients exhibited missing upper central and lateral incisor, upper canine and premolar teeth. Variations in dental morphology included taurodontism, conical-shaped teeth, and notching of the incisal edges. All patients had a short and narrow maxilla which translated into anterior and posterior cross bites. We conclude that, in our BCD syndrome group, the craniofacial skeletal defects are more severe than patients with BCLP. The pattern of tooth agenesis is unusual as it included teeth that are normally highly resistant to agenesis, namely upper central incisor and canine teeth. © 2016 Wiley Periodicals, Inc.

The Drivers of Academic Success in Cleft and Craniofacial Centers: A 10-Year Analysis of over 2000 Publications.

Author(s): Plana, Natalie M; Massie, Jonathan P; Stern, Marleigh J; Alperovich, Michael; Runyan, Christopher M; Staffenberg, David A; Koniaris, Leonidas G; Grayson, Barry H; Diaz-Siso, J Rodrigo; Flores, Roberto L

Source: Plastic and reconstructive surgery; Feb 2017; vol. 139 (no. 2); p. 450-456

Publication Type(s): Journal Article

Abstract:BACKGROUND Cleft and craniofacial centers require significant investment by medical institutions, yet variables contributing to their academic productivity remain unknown. This study characterizes the elements associated with high academic productivity in these centers. METHODS The authors analyzed cleft and craniofacial centers accredited by the American Cleft Palate-Craniofacial Association. Variables such as university affiliation; resident training; number of plastic surgery, oral-maxillofacial, and dental faculty; and investment in a craniofacial surgery, craniofacial orthodontics fellowship program, or both, were obtained. Craniofacial and cleft-related research published between July of 2005 and June of 2015 was identified. A stepwise multivariable linear regression analysis was performed to measure outcomes of total publications, summative impact factor, basic science publications, total journals, and National Institutes of Health funding. RESULTS One hundred sixty centers were identified, comprising 920 active faculty, 34 craniofacial surgery fellowships, and eight craniofacial orthodontic fellowships; 2356 articles were published in 191 journals. Variables most positively associated with a high number of publications were craniofacial surgery and craniofacial orthodontics fellowships ($\beta = 0.608$), craniofacial surgery fellowships ($\beta = 0.231$), number of plastic surgery faculty ($\beta = 0.213$), and university affiliation ($\beta = 0.165$). Variables most positively associated with high a number of journals were craniofacial surgery and craniofacial orthodontics fellowships ($\beta = 0.550$), university affiliation ($\beta = 0.251$), number of plastic surgery faculty ($\beta = 0.230$), and craniofacial surgery fellowship ($\beta = 0.218$). Variables most positively associated with a high summative impact factor were craniofacial surgery and craniofacial orthodontics fellowships ($\beta = 0.648$), craniofacial surgery fellowship ($\beta = 0.208$), number of plastic surgery faculty ($\beta = 0.207$), and university affiliation ($\beta = 0.116$). Variables most positively associated with basic science publications were craniofacial surgery and craniofacial orthodontics fellowships ($\beta = 0.676$) and craniofacial surgery fellowship ($\beta = 0.208$). The only variable associated with National Institutes of Health funding was craniofacial surgery and craniofacial orthodontics fellowship ($\beta = 0.332$). CONCLUSION Participation in both craniofacial surgery and orthodontics fellowships demonstrates the strongest association with academic success; craniofacial surgery fellowship, university affiliation, and number of surgeons are also predictive.

Second premolar agenesis as a subclinical phenotype of isolated cleft palate.

Author(s): Schwartz, J P; Lauris, R C M C; Dalbén, G; Garib, D G

Source: Orthodontics & craniofacial research; Feb 2017; vol. 20 (no. 1); p. 1-7

Publication Type(s): Journal Article

Abstract:To compare the prevalence of dental anomalies in patients with isolated cleft palate with or without hypodontia of the second premolar. A total of 653 patients with isolated cleft palate aged 8-12 years were divided into two groups: G1-subjects without hypodontia of second premolar ($n = 546$) and G2-subjects with hypodontia of at least one-second premolar ($n = 107$). The control group consisted of 107 non-cleft orthodontic patients. Panoramic and periapical radiographs and dental casts were used to analyze the presence of dental anomalies. Intergroup comparisons were performed using the chi-square test complemented by Proportion test and Bonferroni test. G2 presented higher prevalence of hypodontia of other permanent teeth compared to G1 and control. Ectopic eruption of the maxillary canine and tooth transposition were more frequent in patients with a cleft compared to patients without a cleft, without statistical differences. Deciduous molar infra-occlusion and second premolar disto-angulation were less prevalent in G1 and G2 compared to the control group. G2 showed a higher prevalence of complete cleft palate than G1. Patients with cleft palate and second premolar agenesis showed increased prevalence of tooth agenesis and palatally displaced canines. © 2016 John Wiley & Sons A/S. Published by John Wiley & Sons Ltd.

Comparing Modified Huddart-Bodenham Scoring System and GOSLON Yardstick to Assess Dental Arch Relationships in Unilateral Cleft Lip and Palate Patients.

Author(s): Yakob, Muhaini; Rafidah, H Yang; Gu, M; Yang, Y

Source: The Cleft palate-craniofacial journal : official publication of the American Cleft Palate-Craniofacial Association; Jan 2017

Publication Type(s): Journal Article

Abstract: To test the reliability of the modified Huddart-Bodenham (MHB) numerical scoring system and its agreement with the GOSLON Yardstick categorization for assessing the dental arch relationships in unilateral cleft lip and palate (UCLP) cases. A retrospective study. Faculty of Dentistry, The University of Hong Kong. Forty-one nonsyndromic UCLP consecutive patients attending the Joint Cleft Lip/Palate Clinic at Faculty of Dentistry in the University of Hong Kong were selected. Study models at 8 to 10 years old (T1) and 10 to 12 years old (T2) were obtained from each patient. Models were rated with the MHB scoring system and GOSLON Yardstick index. The intra- and interexaminer reliabilities as well as correlation of both scoring systems were evaluated. Furthermore, to investigate the outcome measurements consistency, the MHB scoring system and GOSLON Yardstick were independently used to compare the dental arch relationships from T1 to T2, with the samples split into intervention and nonintervention groups. The MHB scoring system presented good intra- and interexaminer agreement, which were comparable to those of the GOSLON Yardstick. The correlation between the MHB scoring system and GOSLON Yardstick scores was good. Both scoring systems showed similar results when assessing the change in the dental arch relationships from T1 to T2. The MHB scoring system can be used as an alternative method to the commonly used GOSLON Yardstick for assessing dental deformities in UCLP patients. Both scoring systems showed similar results in assessing the improvement in dental arch relationships.

Skoog Primary Periosteoplasty versus Secondary Alveolar Bone Grafting in Unilateral Cleft Lip and Alveolus: Long-Term Effects on Alveolar Bone Formation and Maxillary Growth.

Author(s): Jabbari, Fatima; Hakelius, Malin M; Thor, Andreas L I; Reiser, Erika A; Skoog, Valdemar T; Nowinski, Daniel J

Source: Plastic and reconstructive surgery; Jan 2017; vol. 139 (no. 1); p. 137-148

Publication Type(s): Journal Article

Abstract:BACKGROUND Clefts involving the alveolus are treated using one of two strategies: primary periosteoplasty at the time of lip repair or secondary alveolar bone grafting at mixed dentition. Most teams favor secondary alveolar bone grafting because of its high success rate, and concerns have been raised that primary periosteoplasty may interfere with maxillary growth. However, primary periosteoplasty may obviate the need for future bone grafting and is still practiced in some centers. Few studies compare the long-term outcomes of these two strategies. METHODS Fifty-seven consecutive patients born with unilateral cleft lip and alveolus were studied retrospectively. All patients underwent primary lip repair using Skoog's method; 28 patients underwent primary periosteoplasty at the time of lip repair and the remaining 29 underwent secondary alveolar bone grafting at mixed dentition. Occlusal radiographs obtained at ages 10 and 16 years were analyzed for alveolar bone height. Cephalometric analysis assessed growth at ages 5, 10, and 18 years. RESULTS Seventeen of 28 patients treated using primary periosteoplasty required later secondary bone grafting, and the bone height at age 16 years was lower in the primary periosteoplasty group ($p < 0.0001$). There was a more pronounced decrease in maxillary protrusion

from ages 5 to 10 years in the primary periosteoplasty group ($p < 0.03$). However, at age 18 there was no significant difference in maxillary growth between the two groups. **CONCLUSION** Primary periosteoplasty did not seem to inhibit long-term maxillary growth but was ineffective as a method of reconstructing the alveolar cleft. **CLINICAL QUESTION/LEVEL OF EVIDENCE** Therapeutic, III.

Assessment of complete unilateral cleft lip and palate patients: Determination of factors effecting dental arch relationships.

Author(s): Arshad, Anas Imran; Alam, Mohammad Khursheed; Khamis, Mohd Fadhli

Source: International journal of pediatric otorhinolaryngology; Jan 2017; vol. 92 ; p. 70-74

Publication Type(s): Journal Article

Abstract: **OBJECTIVES** The purpose of the current study was to assess the treatment outcome of non-syndromic patients having complete unilateral cleft lip and palate (CUCLP) by using GOSLON index and to determine any association of pre and/or postnatal factors with the treatment outcome. **MATERIALS AND METHODS** One hundred and one sets of dental models of patients having CUCLP were assessed in this retrospective study. Five examiners that were blinded to case-specific information scored the dental models at two instances with an interval of two weeks to ensure memory bias elimination ($5 \times 101 \times 2 = 1010$ observations). Calibration courses were conducted prior to scoring and each examiner was provided with scoring sheets, pictures of GOSLON reference models and flowcharts explaining the scoring method. **RESULTS** According to GOSLON index, a mean (SD) GOSLON score of 3.04 (1.25) was determined. Based on treatment outcome groups, 62 patients had favorable (grade 1, 2, and 3) and 39 cases had unfavorable (grade 4 and 5) treatment outcome. Chi-square tests revealed a significant association of gender ($P = 0.002$), cheiloplasty ($P = 0.001$) and palatoplasty ($P < 0.001$) with the treatment outcome. These associations were further explored by entering five independent variables in the logistic regression models. **CONCLUSIONS** The current study found an intermediate treatment outcome of CUCLP cases using GOSLON index. Final logistic model showed that gender, cheiloplasty, and palatoplasty had significantly higher odds of influencing outcomes. Identification of these factors provides us an evidence of traditional and outdated surgical methods and encourages clinicians to adopt current techniques to improve treatment outcomes. This implementation will facilitate comparison between the traditional and current techniques of primary surgical repair.

Evaluation of the maxillofacial morphological characteristics of Apert syndrome infants

Author(s): Kakutani H.; Tsukamoto-Takakusagi Y.; Sato Y.; Saito F.; Iida J.; Oyama A.

Source: Congenital Anomalies; Jan 2017; vol. 57 (no. 1); p. 15-23

Publication Type(s): Journal: Article

Abstract: Apert syndrome is a rare craniosynostosis syndrome characterized by irregular craniosynostosis, midface hypoplasia, and syndactyly of the hands and feet. Previous studies analyzed individuals with Apert syndrome and reported some facial and intraoral features caused by severe maxillary hypoplasia. However, these studies were performed by analyzing both individuals who had and those who had not received a palate repair surgery, which had a high impact on the maxillary growth and occlusion. To highlight the intrinsic facial and intraoral features of Apert syndrome, five Japanese individuals with Apert syndrome from 5 years and 2 months to 9 years and 10 months without cleft palate were analyzed in this study. A concave profile and a skeletal Class III jaw-base relationship caused by severe maxillary hypoplasia were seen in all patients. The patients exhibited anterior and posterior crossbites possibly due to a small dental arch of Maxilla. Copyright © 2016 Japanese Teratology Society

Assessment of complete unilateral cleft lip and palate patients: Determination of factors effecting dental arch relationships

Author(s): Arshad A.I.; Alam M.K.; Khamis M.F.

Source: International Journal of Pediatric Otorhinolaryngology; Jan 2017; vol. 92 ; p. 70-74

Publication Type(s): Journal: Article

Abstract: Objectives The purpose of the current study was to assess the treatment outcome of non-syndromic patients having complete unilateral cleft lip and palate (CUCLP) by using GOSLON index and to determine any association of pre and/or postnatal factors with the treatment outcome. Materials and methods One hundred and one sets of dental models of patients having CUCLP were assessed in this retrospective study. Five examiners that were blinded to case-specific information scored the dental models at two instances with an interval of two weeks to ensure memory bias elimination (5 x 101 x 2 = 1010 observations). Calibration courses were conducted prior to scoring and each examiner was provided with scoring sheets, pictures of GOSLON reference models and flowcharts explaining the scoring method. Results According to GOSLON index, a mean (SD) GOSLON score of 3.04 (1.25) was determined. Based on treatment outcome groups, 62 patients had favorable (grade 1, 2, and 3) and 39 cases had unfavorable (grade 4 and 5) treatment outcome. Chi-square tests revealed a significant association of gender (P = 0.002), cheiloplasty (P = 0.001) and palatoplasty (P < 0.001) with the treatment outcome. These associations were further explored by entering five independent variables in the logistic regression models. Conclusions The current study found an intermediate treatment outcome of CUCLP cases using GOSLON index. Final logistic model showed that gender, cheiloplasty, and palatoplasty had significantly higher odds of influencing outcomes. Identification of these factors provides us an evidence of traditional and outdated surgical methods and encourages clinicians to adopt current techniques to improve treatment outcomes. This implementation will facilitate comparison between the traditional and current techniques of primary surgical repair. Copyright © 2016

Periodontal disease and antibiotics

Genome sequence of *Prevotella intermedia* SUNY aB G8-9K-3, a biofilm forming strain with drug-resistance.

Author(s): Moon, Ji-Hoi; Kim, Minjung; Lee, Jae-Hyung

Source: Brazilian journal of microbiology : [publication of the Brazilian Society for Microbiology]; 2017; vol. 48 (no. 1); p. 5-6

Publication Type(s): Journal Article

Available in full text at [Brazilian Journal of Microbiology](#) - from ProQuest

Abstract: *Prevotella intermedia* has long been known to be as the principal etiologic agent of periodontal diseases and associated with various systemic diseases. Previous studies showed that the intra-species difference exists in capacity of biofilm formation, antibiotic resistance, and serological reaction among *P. intermedia* strains. Here we report the genome sequence of *P. intermedia* SUNY aB G8-9K-3 (designated ATCC49046) that displays a relatively high antimicrobial resistant and biofilm-forming capacity. Genome sequencing information provides important clues in understanding the genetic bases of phenotypic differences among *P. intermedia* strains.

Perioceutics in the management of periodontal disease

Author(s): Arunachalam R.; Rajeev V.; Vedam V.; Ganapathy S.; Dhanavel J.

Source: Journal of Young Pharmacists; 2017; vol. 9 (no. 1); p. 8-13

Publication Type(s): Journal: Review

Abstract:Periodontal disease is an immuno-inflammatory condition involving the tissues that surround and support the teeth. Till date back bone of periodontal treatment is still mechanical removal of plaque and calculus deposits from supra and sub gingival environment whereas complete elimination of these deleterious agents are quite unrealistic as the pocket depth increases. Intra pocket administration of drug via local drug delivery system have shown to achieve better clinical results when used as an adjunct to conventional non-surgical periodontal therapy, as periodontal pockets holds gingival crevicular fluid for the controlled release delivery of antimicrobials directly. This has steered the field of perioceutics which involves usage antimicrobial as well as host modulatory agents for the benefit of periodontium. Innovations in Perioceutics have led the researchers to have minimum usage of antibiotics as they develop resistance against microorganisms with side-effects. Presently focus is towards development of new Local Drug Delivery [LDD], host modulating agents, antibodies, biofilm which yield faster and safer results. In the article various locally delivered perioceutic agents are assessed with regard to their purpose, characteristics it possess, effectiveness as a monotherapy, incomparsion to scaling and root planning, and ability to enhance conventional treatment. Furthermore, arguments related with local delivery are addressed.

Low antibiotic resistance among anaerobic Gram-negative bacteria in periodontitis 5 years following metronidazole therapy.

Author(s): Dahlen, G; Preus, H R

Source: Anaerobe; Feb 2017; vol. 43 ; p. 94-98

Publication Type(s): Journal Article

Abstract:The objective of this study was to assess antibiotic susceptibility among predominant Gram-negative anaerobic bacteria isolated from periodontitis patients who 5 years prior had been subject to mechanical therapy with or without adjunctive metronidazole. One pooled sample was taken from the 5 deepest sites of each of 161 patients that completed the 5 year follow-up after therapy. The samples were analyzed by culture. A total number of 85 anaerobic strains were isolated from the predominant subgingival flora of 65/161 patient samples, identified, and tested for antibiotic susceptibility by MIC determination. E-tests against metronidazole, penicillin, amoxicillin, amoxicillin + clavulanic acid and clindamycin were employed. The 73/85 strains were Gram-negative rods (21 Porphyromonas spp., 22 Prevotella/Bacteroides spp., 23 Fusobacterium/Filifactor spp., 3 Campylobacter spp. and 4 Tannerella forsythia). These were all isolated from the treated patients irrespective of therapy procedures (+/-metronidazole) 5 years prior. Three strains (Bifidobacterium spp., Propionibacterium propionicum, Parvimonas micra) showed MIC values for metronidazole over the European Committee on Antimicrobial Susceptibility Testing break point of >4 µg/mL. All Porphyromonas and Tannerella strains were highly susceptible. Metronidazole resistant Gram-negative strains were not found, while a few showed resistance against beta-lactam antibiotics. In this population of 161 patients who had been subject to mechanical periodontal therapy with or without adjunct metronidazole 5 years prior, no cultivable antibiotic resistant anaerobes were found in the predominant subgingival microbiota. Copyright © 2016 Elsevier Ltd. All rights reserved.

Low Biofilm Lysine Content in Refractory Chronic Periodontitis.

Author(s): Levine, Martin; Lohinai, Zsolt; Teles, Ricardo P

Source: Journal of periodontology; Feb 2017; vol. 88 (no. 2); p. 181-189

Publication Date: Feb 2017

Publication Type(s): Journal Article

Abstract:Chronic periodontitis is controlled without antibiotics by scaling and root planing (SRP) to remove dental biofilm. It has been previously reported that the epithelial barrier to bacterial proinflammatory products is impaired when biofilm lysine falls below the minimal content of normal blood plasma. Aims were to examine whether being refractory and requiring antibiotics to supplement SRP were associated with low biofilm lysine contents. Sixteen patients with periodontitis and six periodontally healthy volunteers (HVs) (respective mean ages: 57 ± 6 and 36 ± 8 years) were examined. Patients with periodontitis received SRP and surgery, and HVs received prophylaxis. At quarterly maintenance or prophylaxis visits during the subsequent year, therapeutic response was good (GR, $n = 9$) or poor (PR, $n = 7$; including five cigarette smokers). Biofilm cadaverine, lysine, and other amino acid (AA) contents were determined by liquid chromatography. Cadaverine mole fraction of lysine plus cadaverine (CF) indicated biofilm lysine decarboxylase activity. Biofilm lysine was 0.19 ± 0.10 and 0.20 ± 0.09 $\mu\text{mol}/\text{mg}$ in GRs and HVs, but 0.07 ± 0.03 $\mu\text{mol}/\text{mg}$ in PRs (Kruskal-Wallis: $P < 0.01$). All AAs were depleted in biofilm from smokers, but only lysine was depleted in biofilm from non-smokers. CF was inversely associated with clinical attachment level (CAL) at baseline before therapy in all patients ($R^2 = 0.28$, $P < 0.01$) and with CAL change after therapy in GR ($R^2 = 0.49$, $P < 0.05$). Lysine and cadaverine contents discriminated PRs from GRs and HVs (Wilks' $\lambda = 0.499$, $P < 0.012$). Refractory responses requiring antibiotic therapy result from smoking and/or microbial infections that starve the biofilm and epithelial attachment of lysine. Biofilm CF is associated with periodontitis severity pretherapy and extent of therapeutic response post-therapy.

BMP1 and TLL1 Are Required for Maintaining Periodontal Homeostasis.

Author(s): Wang, J; Massoudi, D; Ren, Y; Muir, A M; Harris, S E; Greenspan, D S; Feng, J Q

Source: Journal of dental research; Jan 2017 ; p. 22034516686558

Publication Date: Jan 2017

Publication Type(s): Journal Article

Abstract:Mutations in bone morphogenetic protein 1 (BMP1) in humans or deletion of BMP1 and related protease tollid like 1 (TLL1) in mice lead to osteogenesis imperfecta (OI). Here, we show progressive periodontal defects in mice in which both BMP1 and TLL1 have been conditionally ablated, including malformed periodontal ligament (PDL) (recently shown to play key roles in normal alveolar bone formation), significant loss in alveolar bone mass ($P < 0.01$), and a sharp reduction in cellular cementum. Molecular mechanism studies revealed a dramatic increase in the uncleaved precursor of type I collagen (procollagen I) and a reduction in dentin matrix protein 1 (DMP1), which is partially responsible for defects in extracellular matrix (ECM) formation and mineralization. We also showed a marked increase in the expression of matrix metalloproteinase 13 (MMP13) and tartrate-resistant acid phosphatase (TRAP), leading to an acceleration in periodontal breakdown. Finally, we demonstrated that systemic application of antibiotics significantly improved the alveolar bone and PDL damage of the knockdown phenotype, which are thus shown to be partially secondary to pathogen-induced inflammation. Together, identification of the novel roles of BMP1 and TLL1 in maintaining homeostasis of periodontal formation, partly via biosynthetic processing of procollagen I and DMP1, provides novel insights into key contributions of the extracellular matrix environment to periodontal homeostasis and contributes toward understanding of the pathology of periodontitis.

Viruses: Bystanders of periodontal disease.**Author(s):** Aggarwal, Titiksha; Lamba, Arundeeep Kaur; Faraz, Farrukh; Tandon, Shruti**Source:** Microbial pathogenesis; Jan 2017; vol. 102 ; p. 54-58**Publication Type(s):** Journal Article Review

Abstract: Bacterial etiology of periodontal disease is an established fact today. However, despite advances in the field of pharmacology with advent of newer and better antibiotics prevalence of the disease could not be abated. Moreover, unpredictable remissions and indefinite pattern in a single host force us to go back to the exact etiology of the disease. Present is a short review highlighting the role and plausible mechanisms by which viruses can affect the development of periodontal disease. This broadens our concept and will help establish a better treatment protocol for periodontal disease. Copyright © 2016 Elsevier Ltd. All rights reserved.

Efficacy of natural and allopathic antimicrobial agents incorporated onto guided tissue regeneration membrane against periodontal pathogens: An in vitro study**Author(s):** Mehrotra N.; Palle A.R.; Gedela R.K.; Vasudevan S.**Source:** Journal of Clinical and Diagnostic Research; Jan 2017; vol. 11 (no. 1)**Publication Type(s):** Journal: Article

Abstract: Introduction: Periodontal disease is one of the most prevalent afflictions worldwide. It is an infection of the periodontium as a result of subgingival colonization of the specific microbiota, leading to loss of attachment, which requires optimal care for regeneration to its pre-disease state. Guided Tissue Regeneration (GTR) is one of the successful treatment modalities in Periodontal Regenerative Therapy, but is vulnerable to bacterial colonization. The conflict between usage of classical antibiotics and plant origin antimicrobial agents has recently been in the limelight. Aim: The aim of this study was to assess the in vitro antimicrobial activity of amoxicillin, metronidazole and green coffee extract loaded onto GTR membrane against periodonto-pathogens. Materials and Methods: Pure form of amoxicillin, metronidazole and green coffee extract were obtained. One percent concentration of each antimicrobial agent was prepared by appropriate dilution with distilled water. GTR membrane was cut into a size of 1x0.5 cm under sterile conditions and was coated with the antimicrobial agents respectively and with distilled water as the negative control. Antimicrobial activity was checked against *Aggregatibacter actinomycetemcomitans* (A. actinomycetemcomitans) and *Porphyromonas gingivalis* (P. gingivalis) using agar disc diffusion method. The statistical analysis was done using Kruskal Wallis ANOVA and Mann-Whitney U test. Results: One percent amoxicillin showed level of significance ($p > 0.05$) against both A. actinomycetemcomitans and P. gingivalis. Green coffee extract showed no zone of inhibition against both the bacterial species. Conclusion: Loading of commercially available antimicrobial agents onto GTR membrane can prevent its bacterial colonization leading to better treatment outcomes for periodontal regeneration. Copyright © 2017, Journal of Clinical and Diagnostic Research. All rights reserved.

Biofilm formation by drug resistant enterococci isolates obtained from chronic periodontitis patients**Author(s):** Bhardwaj S.B.; Mehta M.; Sharma J.; Sood S.**Source:** Journal of Clinical and Diagnostic Research; Jan 2017; vol. 11 (no. 1)

Publication Type(s): Journal: Article

Abstract:Introduction: Enterococci are an important cause of opportunistic nosocomial infections and several multidrug resistant strains have emerged. The severity of periodontal diseases is managed by reduction in the pathogenic bacteria. There is a need to assess the prevalence and antibiotic susceptibility of enterococci colonizing the periodontal pocket and correlate its biofilm formation ability because oral biofilms provide a protective environment and are a reservoir of bacterial colonization of the gingival crevice. Aim: To investigate possible association between antibiotic susceptibility and biofilm formation in enterococci isolates from chronic periodontitis patients. Materials and Methods: This retrospective study was conducted at Dr. Harvansh Singh Judge Institute of Dental Sciences and Hospital, Punjab University, Chandigarh from January 2015 to October 2015. Sterile paper points were inserted in the periodontal pocket of 100 subjects and put in a transport media. Forty -six isolates were identified as enterococci. The isolates were further examined for their ability to form biofilm by microtitre plate assay and antimicrobial susceptibility testing was done by disc diffusion method for clinically relevant antibiotics. Results: Significant relationship ($p < 0.001$) was found between biofilm production with antibiotic resistance to Vancomycin, Erythromycin, Ciprofloxacin, Tetracycline, Amoxicillin and Gentamycin. Conclusion: The study demonstrates a high propensity among the isolates of Enterococci to form biofilm and a significant association of biofilm with multiple drug resistance. Copyright ©2017, Journal of Clinical and Diagnostic Research. All rights reserved.

Dental-related head and neck oncology

Preauricular pilomatricoma: An uncommon entity in a dental pediatric patient

Author(s): Bozkurt P.; Kolsuz M.E.; Orhan K.; Gunhan O.; Erdem E.

Source: International Journal of Surgery Case Reports; 2017; vol. 30 ; p. 62-65

Publication Type(s): Journal: Article

Abstract:Introduction Pilomatricomas are benign follicular skin appendage tumors, commonly occurring in children and young adults. Most patients admit to dermatologists to seek treatment and are well known by them; however, dental professionals, especially pediatric dentists are not familiar with these tumors. Presentation of case This report presents a 16-year-old female with preauricular pilomatricoma, located beneath the overlying skin of the temporomandibular region. Clinical examination revealed an asymptomatic lump, the overlying skin revealed no abnormalities. Patient was unaware of the lesion. Discussion Pilomatricomas are commonly encountered in the maxillofacial region, although not considered in differential diagnosis by dental professionals. They usually present as, asymptomatic, subcutaneous masses; although symptomatic cases have been reported. In literature, common differential diagnosis for head and neck pilomatricoma includes sebaceous cyst, ossifying hematoma, giant cell tumor, chondroma, dermoid cyst, foreign body reaction, degenerating fibroxanthoma, metastatic bone formation, and osteoma cutis. We are of the opinion that temporomandibular joint disease should also be considered in differential diagnosis for preauricular pilomatricoma. Conclusion Pediatric dentists should be aware of the condition and consider it in the differential diagnosis of pediatric conditions involving the temporomandibular joint. Copyright © 2016 The Author(s)

Clinical outcome and morbidity in pediatric patients with nasopharyngeal cancer treated with chemoradiotherapy.

Author(s): Sahai, Puja; Mohanti, Bidhu Kalyan; Sharma, Atul; Thakar, Alok; Bhasker, Suman; Kakkar, Aanchal; Sharma, Mehar Chand; Upadhyay, Ashish Datt

Source: Pediatric blood & cancer; Feb 2017; vol. 64 (no. 2); p. 259-266

Publication Type(s): Journal Article

Abstract:The aim of the study was to evaluate the outcome and treatment-related morbidity in pediatric patients with nasopharyngeal carcinoma (NPC) treated with chemoradiotherapy. We did a retrospective review of 41 pediatric patients diagnosed with NPC between 2000 and 2013. The majority of the patients were treated with neoadjuvant chemotherapy followed by concurrent chemoradiation with the dose of 70 Gy in 35 fractions. Eight patients were treated with intensity-modulated radiation therapy, while the remaining with three-dimensional conformal radiation therapy or two-dimensional simulation technique. The median age of the patients was 14 years (range 6-20 years). Most of the patients had locoregionally advanced disease (stage III/IVA/IVB). The histology of all the cases was undifferentiated carcinoma. Immunohistochemistry for the Epstein-Barr virus-Latent membrane protein 1 was positive in nine of the 13 tested cases. The median follow-up for all and the surviving patients was 26.6 months (range 2-140.8) and 51.2 months, respectively. The 3-year overall survival (OS) and event-free survival (EFS) rates were estimated at 83.7% (95% confidence interval [CI]: 64.8-93%) and 55.8% (95%CI: 38.7-69.8%), respectively. Distant metastases were the predominant pattern of failure. Treatment response showed an independent association with OS. T classification (T1/T2 vs. T3/T4) was significantly associated with EFS. Xerostomia, hypothyroidism, dental caries, neck fibrosis, trismus, and dysphagia were the common late effects in survivors. Radiation myelitis was observed in one patient. Treatment with neoadjuvant chemotherapy followed by concurrent chemoradiation provides good survival outcomes in pediatric NPC. The quality of life of the survivors is a pertinent area that necessitates consideration. © 2016 Wiley Periodicals, Inc.

Oral health and human papillomavirus-associated head and neck squamous cell carcinoma.

Author(s): Mazul, Angela L; Taylor, James M; Divaris, Kimon; Weissler, Mark C; Brennan, Paul; Anantharaman, Devasena; Abedi-Ardekani, Behnoush; Olshan, Andrew F; Zevallos, Jose P

Source: Cancer; Jan 2017; vol. 123 (no. 1); p. 71-80

Publication Type(s): Journal Article

Abstract:Indicators of poor oral health, including smoking, have been associated with increased risk of head and neck squamous cell carcinoma, especially oropharyngeal squamous cell carcinoma (OPSCC), yet few studies have examined whether this association is modified by human papillomavirus (HPV) status. Data from interviews and tumor HPV status from a large population-based case-control study, the Carolina Head and Neck Cancer Study (CHANCE), were used to estimate the association between oral health indicators and smoking among 102 HPV-positive patients and 145 HPV-negative patients with OPSCC and 1396 controls. HPV status was determined by p16INK4a (p16) immunohistochemistry. Unconditional, multinomial logistic regression was used to estimate odds ratios (ORs) for all oral health indicators adjusting for important covariates. Routine dental examinations were associated with a decreased risk of both HPV-negative OPSCC (OR, 0.52; 95% confidence interval [CI], 0.35-0.76) and HPV-positive OPSCC (OR, 0.55; 95% CI, 0.36-.86). Tooth mobility (a proxy for periodontal disease) increased the risk of HPV-negative disease (OR, 1.70; 95% CI, 1.18-2.43) slightly more than the risk for HPV-positive disease (OR, 1.45; 95% CI, 0.95-2.20). Ten or more pack-years of cigarette smoking were strongly associated with an increased risk of HPV-negative OPSCC (OR, 4.26; 95% CI, 2.85-6.37) and were associated less with an increased risk of HPV-positive OPSCC (OR, 1.62; 95% CI, 1.10-2.38). Although HPV-positive and HPV-negative HNSCC differ significantly with respect to etiology and tumorigenesis, the current findings suggest a similar pattern of association between poor oral health, frequency of dental examinations, and both HPV-positive and HPV-negative OPSCC. Future research is required to elucidate interactions

between poor oral health, tobacco use, and HPV in the development of OPSCC. Cancer 2017;71-80.
© 2016 American Cancer Society. © 2016 American Cancer Society.

The influence of dental treatment on the development of osteoradionecrosis after radiotherapy by modern irradiation techniques.

Author(s): Schweyen, Ramona; Stang, Andreas; Wienke, Andreas; Eckert, Alexander; Kuhnt, Thomas; Hey, Jeremias

Source: Clinical oral investigations; Jan 2017

Publication Type(s): Journal Article

Abstract:The aim of this study was to analyze the influence of dental treatment on the development of osteoradionecrosis (ORN) of the jaw. This study included the data of 776 patients who underwent 3D-CRT or IMRT because of head and neck cancer. Sex, dental status before and after radiotherapy (RT), tumor site, bone surgery during tumor operation, concomitant chemotherapy, and the development of an advanced ORN were documented for each patient. The patients' dentitions before and after RT were classified into four groups with regard to the number and localization of the remaining teeth. Differences between the patients with ORN and patients without ORN with regard to the teeth's condition before and after RT, and with regard to the extent of dental treatment were determined descriptively. Cox proportional hazards regression to study the association between dentition and the development of ORN. The extent of dental treatment in patients with and without ORN did not differ in a clinically relevant way. The highest risk of developing ORN was observed in patients who had undergone primary bone surgery during the tumor operation (HR = 5.58, 95%CI 2.91-10.7) and patients who had a tumor in the oral cavity (HR = 4.84, 95%CI 1.37-17.11). Based on the results of this study, tumor localization and its required treatment are prognostic factors for the development of ORN. After implementing a consequent dental treatment scheme, no influence of dentition on the risk of developing ORN could be demonstrated. Patients with a lower risk could prospectively benefit from a more moderate dental treatment scheme.

Dental Prophylaxis and Osteoradionecrosis.

Author(s): Chang, C T; Liu, S P; Muo, C H; Tsai, C H; Huang, Y F

Source: Journal of dental research; Jan 2017 ; p. 22034516687282

Publication Type(s): Journal Article

Abstract:The aim of this study was to investigate the association of different dental prophylactic modalities and osteoradionecrosis (ORN) and determine the risk of ORN under different timing periods of scaling, with the use chlorhexidine mouth rinse after surgery and with different strategies of fluoride gel application in head and neck cancer (HNC) participants. A cohort of 18,231 HNC participants, including 941 ORN patients and 17,290 matched control cases, were enrolled from a Longitudinal Health Insurance Database for Catastrophic Illness Patients (LHID-CIP) in Taiwan. Based on different dental prophylactic modalities before radiotherapy, including chlorhexidine mouth rinse, scaling, and fluoride gel, all HNC subjects were stratified into different groups. The Cox proportional hazard regression was used to compare ORN incidences under different dental prophylactic modalities. The results revealed that scaling and chlorhexidine mouth rinse were significantly related to ORN risk ($P = 0.004$ and $P < 0.0001$). Chlorhexidine mouth rinse was highly correlated to ORN occurrence (hazard ratio [HR], 1.83-2.66), as exposure increased the risk by 2.43-fold among oral cancer patients, regardless of whether they had received major oral surgery or not. Oral cancer patients receiving scaling within 2 wk before radiotherapy increased their incidence of

ORN by 1.28-fold compared with patients who had not undergone scaling within 6 mo. There is no significance of fluoride application for dental prophylaxis in increasing ORN occurrence. In conclusion, dental prophylaxis before radiotherapy is strongly correlated to ORN in HNC patients. Chlorhexidine exposure and dental scaling within 2 wk before radiotherapy is significantly related to ORN risk, especially in oral cancer patients. The use of 1.1% NaF topical application did not significantly increase the risk of ORN in HNC patients. An optimal dental prophylaxis protocol to reduce ORN should concern cancer location, cautious prescription of chlorhexidine mouth rinse, and proper timing of scaling.

Radiotherapy-associated dental extractions and osteoradionecrosis.

Author(s): Beech, Nicholas M; Porceddu, Sandro; Batstone, Martin D

Source: Head & neck; Jan 2017; vol. 39 (no. 1); p. 128-132

Publication Type(s): Journal Article

Available in full text at [Head and Neck](#) - from Ovid

Abstract: Preradiotherapy dental extractions often form a part of the management plan for patients treated with radiotherapy for head and neck cancers in order to prevent complications, such as osteoradionecrosis. There is contention about whether these extractions should be performed and the timing of such extractions. The purpose of this study was to determine if pre-RT extractions were associated with the development of osteoradionecrosis of the jaws. Retrospective data on patients treated with RT for oropharyngeal cancer were pooled with a cross-sectional survey. Pre-radiotherapy dental extractions were associated with a statistically significant increase in the risk of developing ORN. Pre-radiotherapy dental extractions do not protect against the development of osteoradionecrosis. © 2016 Wiley Periodicals, Inc. Head Neck 39: 128-132, 2017. © 2016 Wiley Periodicals, Inc.

Utility of Superiorly Based Masseter Muscle Flap for Postablative Retromaxillary Reconstruction.

Author(s): Bande, Chandrashekhar R; Mishra, Akshay; Gupta, M K; Goel, Manu; Gawande, Mayur J

Source: Journal of oral and maxillofacial surgery : official journal of the American Association of Oral and Maxillofacial Surgeons; Jan 2017; vol. 75 (no. 1); p. 224

Publication Type(s): Journal Article

Abstract: PURPOSE Resections in the posterior component of the oral cavity usually lead to severe functional compromise and lower quality of life for patients. Notable advances in reconstruction of the posterior part of the mouth and of the oropharynx have occurred in recent decades. The anatomic and physiologic rehabilitation of the defect to a reasonable outcome with low morbidity and mortality remains the founding basis of any surgical reconstruction, which also holds true for oral oropharyngeal and retromaxillary reconstructions. PATIENTS AND METHODS A retrospective chart review study of all patients who underwent surgery for retromaxillary malignancy at the Department of Oral and Maxillofacial Surgery, Swargiya Dadasaheb Kalmegh Smruti Dental College and Hospital (Nagpur, India) from 2006 to 2015 was performed. Patients underwent selective neck dissection of levels I to IV using wide local excision. The decision for the type of maxillary resection (marginal ostectomy, partial posterior maxillectomy, or hemimaxillectomy) depended on the degree of osseous infiltration of the tumor. Reconstruction was performed in all cases using the regional masseter muscle flap and advancement of the palatal flap into the defect. The necessary findings and observations were tabulated. RESULTS Of 76 patients who presented at the hospital, 69 had biopsy specimens positive for squamous cell carcinoma and 7 had biopsy specimens positive for

verrucous carcinoma. Twenty-three patients with lesions extending and encroaching into the infratemporal fossa or skull base, distant metastasis, or guarded prognosis were not included in the study. Also excluded from the study were those patients in whom flaps other than the masseteric flap were used primarily for reconstruction. In the remaining 53 patients who underwent resection of retromaxillary malignancy with masseter muscle reconstruction, 48 showed a satisfactory outcome. Postoperative infection was noted in 5 patients and 2 of these patients needed debridement. Postoperative wound contracture with muscular spasm and decreased mouth opening in the early postoperative period were a general observation. In all patients, the vitality of the flap was excellent, with epithelization and adequate mouth opening within 3 weeks. Postoperative speech, swallowing, and facial esthetics were satisfactory and acceptable. **CONCLUSION** The masseter muscle flap is a promising reconstruction alternative for retromaxillary reconstruction because of advantages such as regional access, ease of harvesting, optimum bulk, flexibility, pliability for larger defects, and minimum postoperative morbidity.

Utility of Superiorly Based Masseter Muscle Flap for Postablative Retromaxillary Reconstruction

Author(s): Bande C.R.; Mishra A.; Goel M.; Gupta M.K.; Gawande M.J.

Source: Journal of Oral and Maxillofacial Surgery; Jan 2017; vol. 75 (no. 1); p. 224

Publication Type(s): Journal: Article

Abstract: Purpose Resections in the posterior component of the oral cavity usually lead to severe functional compromise and lower quality of life for patients. Notable advances in reconstruction of the posterior part of the mouth and of the oropharynx have occurred in recent decades. The anatomic and physiologic rehabilitation of the defect to a reasonable outcome with low morbidity and mortality remains the founding basis of any surgical reconstruction, which also holds true for oral oropharyngeal and retromaxillary reconstructions. Patients and Methods A retrospective chart review study of all patients who underwent surgery for retromaxillary malignancy at the Department of Oral and Maxillofacial Surgery, Swargiya Dadasaheb Kalmegh Smruti Dental College and Hospital (Nagpur, India) from 2006 to 2015 was performed. Patients underwent selective neck dissection of levels I to IV using wide local excision. The decision for the type of maxillary resection (marginal ostectomy, partial posterior maxillectomy, or hemimaxillectomy) depended on the degree of osseous infiltration of the tumor. Reconstruction was performed in all cases using the regional masseter muscle flap and advancement of the palatal flap into the defect. The necessary findings and observations were tabulated. Results Of 76 patients who presented at the hospital, 69 had biopsy specimens positive for squamous cell carcinoma and 7 had biopsy specimens positive for verrucous carcinoma. Twenty-three patients with lesions extending and encroaching into the infratemporal fossa or skull base, distant metastasis, or guarded prognosis were not included in the study. Also excluded from the study were those patients in whom flaps other than the masseteric flap were used primarily for reconstruction. In the remaining 53 patients who underwent resection of retromaxillary malignancy with masseter muscle reconstruction, 48 showed a satisfactory outcome. Postoperative infection was noted in 5 patients and 2 of these patients needed debridement. Postoperative wound contracture with muscular spasm and decreased mouth opening in the early postoperative period were a general observation. In all patients, the vitality of the flap was excellent, with epithelization and adequate mouth opening within 3 weeks. Postoperative speech, swallowing, and facial esthetics were satisfactory and acceptable. **Conclusion** The masseter muscle flap is a promising reconstruction alternative for retromaxillary reconstruction because of advantages such as regional access, ease of harvesting, optimum bulk, flexibility, pliability for larger defects, and minimum postoperative morbidity. Copyright © 2016 American Association of Oral and Maxillofacial Surgeons

Dental implants

Treatment of Postextraction Sites With Allograft-Stabilized Dental Implants: A Clinical Case Series.

Author(s): Bianconi, Stefano; Bozzoli, Paolo; Del Fabbro, Massimo

Source: Implant dentistry; Feb 2017; vol. 26 (no. 1); p. 37-45

Publication Type(s): Journal Article

Abstract: Additional grafting procedures for the treatment of extremely atrophic jaws may be demanding, expensive, and sometimes require long time and multiple surgical sessions, which may reduce patient's acceptance and quality of life. This study evaluated the outcomes of 10 patients with extensive alveolar bone defects in the posterior jaws, treated in a single surgical session with grafting and implants. Ten consecutive patients were treated within 3 months of extraction. After ridge exposure, implants were positioned in 4-wall defects without contact with pristine bone, and mineralized particulate allograft packed around to stabilize them. Sites were covered with resorbable membranes and soft tissues were sutured tension-free. Five months later, implants were restored in centric occlusion. At uncovering, newly formed bone filled all defects and all implants resisted at 30 Ncm of reverse torque. No complication was recorded throughout the study; survival rate was 100% for both implants and grafts. After 24 months of follow-up, mean periimplant bone level change was 0.15 ± 0.53 mm and mean bone gain at the defect site was 11.62 ± 1.04 mm. Rehabilitation of wide postextraction defects may achieve successful outcomes using allograft and a special implant design, even in the absence of optimal primary stability.

Comparison of clinical and radiographic status around dental implants placed in patients with and without prediabetes: 1-year follow-up outcomes.

Author(s): Al Amri, Mohammad D; Abduljabbar, Tariq S; Al-Kheraif, Abdulaziz A; Romanos, Georgios E; Javed, Fawad

Source: Clinical oral implants research; Feb 2017; vol. 28 (no. 2); p. 231-235

Publication Date: Feb 2017

Publication Type(s): Journal Article

Abstract: **OBJECTIVE** We hypothesized that peri-implant soft tissue inflammation is worse and peri-implant marginal bone loss (MBL) is higher around dental implants placed in patients with prediabetes compared to healthy subjects. The aim of the present 12-month follow-up study was to compare the clinical and radiographic status around dental implants placed in patients with and without prediabetes. **MATERIAL AND METHODS** Twelve patients with medically diagnosed prediabetes (Group-1) and 12 controls (Group-2) were included. All patients were indicated for single tooth maxillary or mandibular premolar replacement with the adjacent teeth intact. Success of the restored implants was assessed by comparing clinical (peri-implant bleeding on probing [BOP], and probing pocket depth [PPD]) and radiographic (peri-implant MBL) parameters at baseline and at 12-months follow-up. Statistical analysis was performed using one-way analysis of variance, and P-values <0.05 were considered statistically significant. **RESULTS** At 12 months of follow-up, there was no clinical evidence for the presence of plaque, BOP and peri-implant pockets with $PPD \geq 4$ mm in both groups. At 12-month follow-up, the mean MBL among implants placed in groups 1 and 2 were 0.2 ± 0.1 mm and 0.1 ± 0.01 mm, respectively. Overall, the periodontal status (PI, BOP and $PPD \geq 4$ mm) at 12-month follow-up was comparable among patients in both groups. **CONCLUSION** Within the limitations of this study, it is concluded that dental implants inserted in prediabetic and healthy patients have similar success rates and remain clinically and radiographically stable after 1-year follow-up.

Long-term outcomes of dental implants placed in elderly patients: a retrospective clinical and radiographic analysis.

Author(s): Park, Jung-Chul; Baek, Won-Sun; Choi, Seong-Ho; Cho, Kyoo-Sung; Jung, Ui-Won

Source: Clinical oral implants research; Feb 2017; vol. 28 (no. 2); p. 186-191

Publication Type(s): Journal Article

Abstract:OBJECTIVES The aim of this retrospective study was to determine the clinical and the radiographic outcomes of dental implants placed in elderly people older than 65 years. MATERIALS AND METHODS In total, 902 implants in 346 patients (age: 65-89 years) were followed up for 2-17 years following the implant surgery. The survival rate of these implants was recorded and analyzed. Changes in marginal bone levels were also analyzed in serial radiographs, and Cox regression analysis for implant loss was performed. RESULTS The survival rates were 95.39% and 99.98% in the implant- and patient-based analyses, respectively (involving a total of 29 implant failures), and the marginal bone loss at the implants was 0.17 ± 0.71 mm (mean \pm SD). The number of failures was greatest in patients aged 65-69 years. The Cox regression with shared frailty analysis showed that implant loss was significantly greater in those aged 65-69 years than in those aged 70-74 years ($P < 0.05$), and it varied between specific implant systems. CONCLUSIONS Within the limitations of this retrospective study, it was concluded that implant therapy can be successfully provided to elderly patients and that age alone does not seem to affect the implant survival rate.

Stability and Crestal Bone Behavior Following Simultaneous Placement of Multiple Dental Implants (Two or More) with the Bone Splitting Technique: A Clinical and Radiographic Evaluation.

Author(s): Gehrke, Sergio Alexandre; Maté Sánchez de Val, José Eduardo; Ramírez Fernández, Maria Piedad; Shibli, Jamil Awad; Rossetti, Paulo Henrique Orlato; Calvo Guirado, José Luis

Source: Clinical implant dentistry and related research; Feb 2017; vol. 19 (no. 1); p. 123-130

Publication Type(s): Journal Article

Abstract:The present study aimed to measure the implant stability quotient (ISQ) values at three different time points after surgical procedures and crestal bone behavior in multiple implants (two or more) installed simultaneously with the bone splitting technique. For this study, 45 patients with different edentulous areas in the maxilla were selected, and a total of 114 dental implants were installed. Implant stability was measured by resonance frequency analysis immediately following implant placement to assess immediate stability (time 1) and stability at 90 days (time 2), and 150 days (time 3). Crestal bone height was measured in peri-apical radiographs at 90 and 150 days after implantation in relation to each implant shoulder, given that the implants were installed at the level of the crestal bone. Six implants were not osseointegrated. Overall, the means and standard deviations of the ISQ values were 60.3 ± 4.94 (95% confidence interval [CI], 44-69) at baseline, 66.6 ± 5.28 (95% CI, 49-75) at 90 days, and 72.1 ± 4.28 (95% CI, 59-79) at 150 days ($p < 0.0001$). The mean marginal bone loss of the implants was 1.11 ± 0.61 mm on the mesial side and 1.17 ± 0.61 mm on the distal side at time 2, and 1.73 ± 0.68 mm on the mesial side and 1.79 ± 0.70 mm on the distal side at time 3. A strong positive correlation between implant stability and bone loss was detected ($p < 0.0001$). Within the limits of this study, the bone splitting technique with simultaneous implant installation exhibited a good success rate with respect to the osseointegration index but requires attention with respect to crestal bone behavior. © 2016 Wiley Periodicals, Inc.

Osseointegration of titanium, titanium alloy and zirconia dental implants: current knowledge and open questions.

Author(s): Bosshardt, Dieter D; Chappuis, Vivianne; Buser, Daniel

Source: Periodontology 2000; Feb 2017; vol. 73 (no. 1); p. 22-40

Publication Type(s): Journal Article Review

Abstract: Bone healing around dental implants follows the pattern and sequence of intramembraneous osteogenesis with formation of woven bone first of all followed later by formation of parallel-fibered and lamellar bone. Bone apposition onto the implant surface starts earlier in trabecular bone than in compact bone. While the first new bone may be found on the implant surface around 1 week after installation, bone remodeling starts at between 6 and 12 weeks and continues throughout life. Bone remodeling also involves the bone-implant interface, thus transiently exposing portions of the implant surface. Surface modifications creating micro-rough implant surfaces accelerate the osseointegration process of titanium implants, as demonstrated in numerous animal experiments. Sandblasting followed by acid-etching may currently be regarded as the gold standard technique to create micro-rough surfaces. Chemical surface modifications, resulting in higher hydrophilicity, further increase the speed of osseointegration of titanium and titanium-zirconium implants in both animals and humans. Surface modifications of zirconia and alumina-toughened zirconia implants also have an influence on the speed of osseointegration, and some implant types reach high bone-to-implant contact values in animals. Although often discussed independently of each other, surface characteristics, such as topography and chemistry, are virtually inseparable. Contemporary, well-documented implant systems with micro-rough implant surfaces, placed by properly trained and experienced clinicians, demonstrate high long-term survival rates. Nevertheless, implant failures do occur. A low percentage of implants are diagnosed with peri-implantitis after 10 years in function. In addition, a low number of implants seem to be lost for primarily reasons other than biofilm-induced infection. Patient factors, such as medications interfering with the immune system and bone cells, may be an element contributing to continuous bone loss and should therefore be monitored and studied in greater detail. © 2016 John Wiley & Sons A/S. Published by John Wiley & Sons Ltd.

Clinical and radiological investigations of mandibular overdentures supported by conventional or mini-dental implants: A 2-year prospective follow-up study.

Author(s): Temizel, Sonay; Heinemann, Friedhelm; Dirk, Cornelius; Bourauel, Christoph; Hasan, Istabrak

Source: The Journal of prosthetic dentistry; Feb 2017; vol. 117 (no. 2); p. 239

Publication Type(s): Journal Article

Abstract: Conventional dental implants are not applicable in the mandibular interforaminal region if bone volume is limited. Mini-dental implants offer an alternative means of supporting mandibular overdentures in a narrow residual ridge, without additional surgery. The purpose of this nonrandomized clinical trial was to compare the ability of mini-dental implants with that of conventional dental implants in supporting mandibular overdentures during a 2-year clinical follow-up. Bone quality, bone resorption, implant stability, and oral health were assessed radiographically. A total of 32 participants with edentulism were included. Twenty-two participants (99 implants) received 4 to 5 mini-dental implants (diameter: 1.8-2.4 mm; length: 13-15 mm, study group), and 10 participants (35 implants) received 2 to 4 conventional dental implants (diameter: 3.3-3.7 mm; length: 11-13 mm, control group). The selection of the participants in the study or control group was based on the available bone volume in the mandible. The selection was not randomized. The density of cortical bone thickness was measured in Hounsfield units (HU) from computed tomography data,

and patients were followed for 2 years. The participants were examined 3, 6, 12, and 24 months after surgery. Primary stability immediately after the insertion of dental implants (Periotest), secondary stability 6 months after implantation, modified plaque, bleeding on probing indices, and probing depth were measured and analyzed statistically ($\alpha=.05$). The mean HU value 6 months after implantation in the participants who received mini-dental implants was significantly ($P=.035$) higher (1250 HU) than that in the participants who received conventional dental implants (1100 HU). The probing depths around the conventional dental implants (1.6 and 1.8 mm, respectively) were significantly higher than those around the mini-dental implants (1.3 and 1.2 mm, respectively) 12 and 24 months after surgery, respectively ($P<.001$). The mean primary and secondary stability values for conventional dental implants were -4.0 and -4.9, respectively. The primary and secondary stability values for the mini-dental implants were -0.3 and -1.4, respectively. The Periotest values of the primary (measured immediately after implant insertion) and secondary implant stabilities (measured 6 months after implant insertion) were significantly higher for the conventional dental implants than for the mini-dental implants ($P<.001$). Based on this 2-year clinical trial, patients receiving mini-dental implants had clinical outcomes similar to those of patients receiving conventional dental implants to support overdenture prostheses. Copyright © 2016 Editorial Council for the Journal of Prosthetic Dentistry. Published by Elsevier Inc. All rights reserved.

The split crest technique and dental implants: a systematic review and meta-analysis

Author(s): Waechter J.; Leite F.R.; Nascimento G.G.; Carmo Filho L.C.; Faot F.

Source: International Journal of Oral and Maxillofacial Surgery; Jan 2017; vol. 46 (no. 1); p. 116-128

Publication Type(s): Journal: Review

Abstract: This systematic review aimed to determine: (1) the expected bone volume gain with the split crest technique, and (2) how the use of surgical instruments affects the performance of this technique. An electronic search was performed in the Cochrane Central Register of Controlled Trials, ClinicalTrials.gov, Embase, PubMed/MEDLINE, Scopus, and Web of Science databases. Twenty-seven articles met the selection criteria and were subjected to meta-analysis of bone gain and survival rate; 17 reported the use of conventional surgical instruments and nine the use of surgical ultrasound. A total of 4115 implants were installed in 1732 patients (average patient age 52 years). The overall implant survival rate was 97%. The average bone gain in studies that used conventional surgical instruments was 3.61 mm, while this was 3.69 mm in those that used ultrasound. Only two studies presented a low risk of bias. The greatest problems identified during the qualitative analysis were related to random selection of the population and the absence of statistical analysis. The split crest technique appears to be a promising and effective technique to gain bone width, regardless of the surgical instruments used. Considering the diversity of the studies and implant types, no definitive recommendations can be made, especially with regard to the best instruments and implant design to be used. Copyright © 2016 International Association of Oral and Maxillofacial Surgeons

Short dental implants (6 mm) versus long dental implants (11-15 mm) in combination with sinus floor elevation procedures: 3-year results from a multi-center, randomized, controlled clinical trial.

Author(s): Pohl, Veronika; Thoma, Daniel S; Sporniak-Tutak, Katarzyna; Garcia-Garcia, Abel; Taylor, Thomas D; Haas, Robert; Hämmerle, Christoph H F

Source: Journal of clinical periodontology; Jan 2017

Publication Type(s): Journal Article

Abstract:To test whether or not the use of short dental implants (6 mm) results in an implant survival rate similar to that with longer implants (11-15 mm) in combination with sinus grafting. This multi-center study enrolled 101 patients with partial edentulism in the posterior maxilla and a remaining bone height of 5-7 mm. Included patients were randomly assigned to receive short implants (6 mm; GS / group short) or long implants (11-15 mm) simultaneously with sinus grafting (GG / group graft). Six months after implant placement (IP), implants were loaded with single crowns (PR) and patients were re-examined yearly thereafter. Assessed outcomes included: implant survival, marginal bone level changes (MBL), probing pocket depth (PPD), bleeding on probing (BoP) and plaque accumulation (PCR) during 3 years of loading as well as recording of any adverse effects. In addition to descriptive statistics, statistical analysis has been performed for the two treatment modalities using a non-parametric approach. In 101 patients, 137 implants were placed. At the 3-year follow-up (FU-3), 94 patients with 129 implants were re-examined. The implant survival rate was 100% in both groups. MBL at FU-3 was 0.45 mm (GG) and 0.44 mm (GS) ($p > .05$). A statistically significant loss of MBL was observed in both GG ($-0.43\text{mm} \pm 0.58\text{mm}$) and GS ($-0.44\text{mm} \pm 0.56\text{mm}$) from IP to FU-3, and from PR to FU-3 in GG ($-0.25\text{mm} \pm 0.58\text{mm}$) but not in GS ($-0.1\text{mm} \pm 0.54\text{mm}$). PCR and BoP at FU-3 did not show any difference between the groups but for PPD ($p = 0.035$). Within the limitations of this study implants with a length of 6 mm as well as longer implants in combination with a lateral sinus lift may be considered as a treatment option provided a residual ridge height of 5-7 mm in the atrophied posterior maxilla is present. This article is protected by copyright. All rights reserved. This article is protected by copyright. All rights reserved.

Soft tissue augmentation around osseointegrated and uncovered dental implants: a systematic review.

Author(s): Bassetti, Renzo G; Stähli, Alexandra; Bassetti, Mario A; Sculean, Anton

Source: Clinical oral investigations; Jan 2017; vol. 21 (no. 1); p. 53-70

Publication Type(s): Journal Article Review

Abstract:The aim was to compile the current knowledge about the efficacy of different soft tissue correction methods around osseointegrated, already uncovered and/or loaded (OU/L) implants with insufficient soft tissue conditions. Procedures to increase peri-implant keratinized mucosa (KM) width and/or soft tissue volume were considered. Screening of two databases: MEDLINE (PubMed) and EMBASE (OVID), and manual search of articles were performed. Human studies reporting on soft tissue augmentation/correction methods around OU/L implants up to June 30, 2016, were considered. Quality assessment of selected full-text articles to weight risk of bias was performed using the Cochrane collaboration's tool. Overall, four randomized controlled trials (risk of bias = high/low) and five prospective studies (risk of bias = high) were included. Depending on the surgical techniques and graft materials, the enlargement of keratinized tissue (KT) ranged between 1.15 ± 0.81 and 2.57 ± 0.50 mm. The apically positioned partial thickness flap (APPTF), in combination with a free gingival graft (FGG), a subepithelial connective tissue graft (SCTG), or a xenogeneic graft material (XCM) were most effective. A coronally advanced flap (CAF) combined with SCTG in three, combined with allogenic graft materials (AMDA) in one, and a split thickness flap (STF) combined with SCTG in another study showed mean soft tissue recession coverage rates from 28 to 96.3 %. STF combined with XCM failed to improve peri-implant soft tissue coverage. The three APPTF-techniques combined with FGG, SCTG, or XCM achieved comparable enlargements of peri-implant KT. Further, both STF and CAF, both in combination with SCTG, are equivalent regarding recession coverage rates. STF + XCM and CAF + AMDA did not reach significant coverage. In case of soft tissue deficiency around OU/L dental implants, the selection of both an appropriate surgical technique and a suitable soft tissue graft material is of utmost clinical relevance.

Long-term prospective cohort study on dental implants: clinical and microbiological parameters.

Author(s): Tenenbaum, Henri; Bogen, Omer; Séverac, François; Elkaim, René; Davideau, Jean-Luc; Huck, Olivier

Source: Clinical oral implants research; Jan 2017; vol. 28 (no. 1); p. 86-94

Publication Type(s): Journal Article

Abstract:The aim of the present prospective cohort study is to evaluate clinical and microbiological data of dental implants after at least 8 years of follow-up. A total of 110 patients and 232 implants were included at baseline and followed during 1 year. Fifty-two patients and 108 implants could be evaluated at the final examination. Clinical and microbiological data were taken at baseline, 1 year and at least 8 years. The mean follow-up time was 10.8 ± 1.7 years. Plaque index was, respectively, 0.50 ± 0.50 at baseline, 0.50 ± 0.50 at 1 year and 0.33 ± 0.67 at ≥ 8 years. Gingival index was, respectively, 1.08 ± 0.19 at baseline, 1.01 ± 0.39 at 1 year and 0.22 ± 0.47 at ≥ 8 years. Sulcular bleeding index was, respectively, 0.17 ± 0.22 at baseline, 0.11 ± 0.33 at 1 year and 0.17 ± 0.22 at ≥ 8 years. Probing depth was, respectively, 2.67 ± 0.75 at baseline, 3.00 ± 0.83 at 1 year and 2.74 ± 1.00 at ≥ 8 years. Clinical attachment level was, respectively, 3.75 ± 1.17 at baseline, 4.00 ± 1.06 at 1 year and 4.00 ± 1.17 at ≥ 8 years. Peri-implant mucositis was detected around 60.2% of implants in 73.1% of patients, while peri-implantitis was affecting 12% of implants in 15.4% of patients. Some bacteria species were associated with worsened clinical parameters. About 69.4% of implants (75/108) and 67.3% of the patients (35/52) were considered as success in the present prospective cohort study after a mean follow-up of 10.8 years. Microbial follow-up may help to identify patients at risk for peri-implant disease. © 2016 John Wiley & Sons A/S. Published by John Wiley & Sons Ltd.

Clinicopathologic evaluation of malignancy adjacent to dental implants.

Author(s): Kaplan, Ilana; Zeevi, Itai; Tal, Haim; Rosenfeld, Eli; Chaushu, Gavriel

Source: Oral surgery, oral medicine, oral pathology and oral radiology; Jan 2017; vol. 123 (no. 1); p. 103-112

Publication Type(s): Journal Article

Abstract:The aim of this study was to describe a new case series of peri-implant malignancy, review the literature, and discuss the implications of malignancies resembling peri-implantitis. This study was a retrospective analysis of cases from 2000 to 2016. Seven patients (two males and five females), aged 44 to 89 years, were included, representing 1.5% of oral malignancy cases. Five cases were squamous carcinoma, one of basal cell carcinoma, and one of carcinoma of metastatic origin. Six cases presented with nonulcerated overgrowth, with bone loss in three and massive osteolysis in one. Misinterpretation as peri-implantitis delayed diagnosis in six cases. Risk factors included previous oral malignancy (2), potentially malignant conditions (2), and smoking (1). Of the 47 cases in the English language literature, 85% were squamous cell carcinoma and 8.5% had distant metastasis. Most cases had one or more risk factors. Peri-implant malignancy may represent up to 1.5% of oral malignancy cases. Clinical features imitating peri-implantitis may delay diagnosis. Lesions failing to respond to treatment, especially in patients with pre-existing risk factors, should significantly increase suspicion. Histopathology is crucial for diagnosis. Copyright © 2016 Elsevier Inc. All rights reserved.

Six-Year Survival of a Mini Dental Implant-Retained Overdenture in a Child with Ectodermal Dysplasia.

Author(s): Kilic, Serdar; Altintas, Subutay Han; Yilmaz Altintas, Nuray; Ozkaynak, Ozkan; Bayram, Mehmet; Kusgoz, Adem; Taskesen, Fatih

Source: Journal of prosthodontics : official journal of the American College of Prosthodontists; Jan 2017; vol. 26 (no. 1); p. 70-74

Publication Type(s): Journal Article

Abstract:Patients with ectodermal dysplasia (ED) experience several problems caused by abnormal development and functioning of the head and neck region. In addition to developmental nasal cartilage abnormalities and absence of sweat glands, hair, and eyebrows, edentulism or developmental disorders of teeth (cone-shaped teeth) are commonly observed in these types of patients. ED is also characterized by underdeveloped alveolar ridges, a decreased occlusal vertical dimension, reduced salivary secretion, and dry oral mucosa, which make prosthetic rehabilitation difficult. Few studies of intraosseous dental implant-retained prostheses have described adverse effects on craniofacial growth and esthetic and functional disadvantages, while some researchers have described the advantages of this treatment option as an alternative option in these cases. Due to the associated alveolar bone deficiency, dental mini-implant therapy may be a treatment option for these patients; however, there are isolated cases in the literature regarding the rehabilitation of ED patients with mini-implant-supported overdentures. This clinical report describes the rehabilitation of a 6-year-old child with ED using a maxillary removable partial prosthesis and a mini-implant-retained mandibular overdenture. The clinical and radiographic findings of this prosthetic rehabilitation during the 6-year follow-up are also presented. © 2015 by the American College of Prosthodontists.

Clinical guidelines and procedures for provision of mandibular overdentures on 4 mini-dental implants.

Author(s): Kanazawa, Manabu; Feine, Jocelyne; Esfandiari, Shahrokh

Source: The Journal of prosthetic dentistry; Jan 2017; vol. 117 (no. 1); p. 22-27

Publication Type(s): Journal Article

Abstract:This article describes the flapless placement of mini-dental implants (MDI) to retain mandibular overdentures. Clinical inclusion/exclusion criteria and clinical protocols for the flapless placement of MDIs and for retrofitting the overdenture are presented. A minimum bone height of 13 mm and a minimal flap are recommended. After drilling, the 4 implants are placed with a self-tapping process. A minimum of 15 Ncm of resistance upon final insertion indicates that immediate loading can be performed. The metal housings with O-rings are incorporated into the prosthesis using autopolymerizing resin. The technique and protocol for immediately loaded 4-mini-implant mandibular overdentures is minimally invasive and cost effective. Copyright © 2016 Editorial Council for the Journal of Prosthetic Dentistry. Published by Elsevier Inc. All rights reserved.

Bleeding on probing around dental implants: a retrospective study of associated factors.

Author(s): Farina, Roberto; Filippi, Marco; Brazzioli, Jessica; Tomasi, Cristiano; Trombelli, Leonardo

Source: Journal of clinical periodontology; Jan 2017; vol. 44 (no. 1); p. 115-122

Publication Type(s): Journal Article

Abstract:To (i) identify factors associated with the probability of a peri-implant site to be positive to bleeding on probing (BoP+) and (ii) compare BoP+ probability around dental implants and contra-

lateral teeth. In 112 patients, data related to 1725 peri-implant sites and 1020 contra-lateral dental sites were retrospectively obtained. To analyse the association between patient-, implant- and site-related factors and BoP+ probability, a logistic, three-level model was built with BoP as the binary outcome variable (+/-). BoP+ probability for a peri-implant site with probing depth (PD) of 4 mm was 27%, and the odds ratio increased by 1.6 for each 1-mm increment in PD ($p < 0.001$). Also, BoP+ probability was higher in females compared to males (OR = 1.61; $p = 0.048$), and lower at posterior compared to anterior dental implants (OR = 0.55; $p < 0.01$). No significant difference in BoP+ probability was observed between peri-implant and contra-lateral dental sites when controlling for the difference in PD. The probability of a peri-implant site to bleed upon probing is (i) associated with PD, implant position and gender, and (ii) similar to that observed at contra-lateral dental sites when controlling for the effect of PD. © 2016 John Wiley & Sons A/S. Published by John Wiley & Sons Ltd.

Rehabilitation of the Work Accident-Related Traumatic Mandible With Iliac Free Flap, Distraction Osteogenesis, and Dental Implants.

Author(s): Findik, Yavuz; Baykul, Timuçin; Aydın, Mustafa Asim; Altuntaş, Selman; Demirekin, Zeynep Başağaoğlu

Source: The Journal of craniofacial surgery; Jan 2017

Publication Type(s): Journal Article

Abstract: Mandibular bone defects due to extensive trauma impair occlusion and affect the aesthetics of facial contouring, making it difficult to obtain a satisfactory outcome. Distraction osteogenesis and free flap is an effective and aesthetic treatment option for rehabilitating these defects. In this clinical report, the authors present rehabilitation of a wide mandibular traumatic defect due to a work-related accident with iliac free flap, distraction osteogenesis, and dental implants.

Comparative 3D micro-CT and 2D histomorphometry analysis of dental implant osseointegration in the maxilla of minipigs.

Author(s): Bissinger, Oliver; Probst, Florian Andreas; Wolff, Klaus-Dietrich; Jeschke, Anke; Weitz, Jochen; Deppe, Herbert; Kolk, Andreas

Source: Journal of clinical periodontology; Jan 2017

Publication Date: Jan 2017

Publication Type(s): Journal Article

Abstract: The bone implant contact (BIC) has traditionally been evaluated with histological methods. Thereupon, strong correlations of 2-dimensional (2D) BIC have been detected between μ CT and destructive histology. However, due to the high intra-sample variability of BIC values, one histological slice is not sufficient to represent 3D BIC. Therefore, our aim has been to correlate the averaged values of 3-4 histological sections to 3D μ CT. Fifty four implants inserted into the maxilla of 14 minipigs were evaluated. Two different time points were selected to assess the 3D BIC (distance to implant: 2-5 voxels), an inner ring (6-30 voxels) and an outer ring (55-100 voxels) by using μ CT (voxel size: 10 μ m) and to correlate the values to histomorphometry. Strong correlations ($p < 0.0001$; 28d, 56d, total) were seen between μ CT and histomorphometry concerning BIC ($r = 0.84$, $r = 0.85$, $r = 0.83$), the inner ring ($r = 0.87$, $r = 0.87$, $r = 0.88$) and the outer ring ($r = 0.85$, $r = 0.85$, $r = 0.88$). Closer to the implant, μ -CT values were higher compared with histomorphometry. Although 3-4 histological slices per implant seem to predict the 3D BIC, μ CT might be advantageous because of

its nondestructive 3D character. The healing time may not impact on the comparability. This article is protected by copyright. All rights reserved. This article is protected by copyright. All rights reserved.

Cement-associated peri-implant mucositis. A 1-year follow-up after excess cement removal on the peri-implant tissue of dental implants.

Author(s): Korsch, Michael; Walther, Winfried; Bartols, Andreas

Source: Clinical implant dentistry and related research; Jan 2017

Publication Type(s): Journal Article

Abstract: Methacrylate-based cements seem to promote peri-implant tissue inflammation even in the absence of excess cement. The present study deals with the question of whether the removal of methacrylate cement from the peri-implant sulcus will lead to peri-implant tissues free of inflammation on a 1-year follow-up basis. Implant supported suprastructures that had been in the mouth for at least 3.5 years either cemented with methacrylate (premier implant cement [PIC]) or zinc eugenol (temp bond [TB]) cement were compared. All superstructures in 33 patients with a total of 61 implants (35 with PIC and 26 with TB) were removed and excess cement, bleeding on probing (BOP), suppuration and probing depth were documented. Excess cement found was removed, and in all cases the suprastructure was recemented with TB. Patients were followed up after 4 weeks (F1) and 1 year (F2). Excess cement was found around 60% of the implants with PIC. No excess cement was found around implants with TB. At the time of revision therapy, BOP was found around 100% of the implants with PIC and excess cement (PIC+), 93% around implants with PIC but no excess cement (PIC-), and around 42% of the TB-cemented implants (Chi-squared $P < .01$). Suppuration was observed in 86% of the PIC+ implants, in 14% of the PIC- implants and in 0% of the TB implants (Chi-squared $P < .01$). At the time of both F1 and F2, the inflammation parameters, that is BOP and suppuration, on implant level were significantly reduced in the PIC+ cases (McNemar's test $P < .01$). For PIC-, BOP was significantly reduced at both points in time ($P < .05$). For TB no differences were found. Probing depth at F2 had significantly decreased in all groups (t test $P < .05$). The removal of excess cement and recementation with TB had an anti-inflammatory effect on the peri-implant tissues after 1 year. © 2017 Wiley Periodicals, Inc.

Dimensional soft tissue changes following soft tissue grafting in conjunction with implant placement or around present dental implants: a systematic review.

Author(s): Poskevicius, Lukas; Sidlauskas, Antanas; Galindo-Moreno, Pablo; Juodzbaly, Gintaras

Source: Clinical oral implants research; Jan 2017; vol. 28 (no. 1); p. 1-8

Publication Date: Jan 2017

Publication Type(s): Journal Article Review

Abstract: To systematically review changes in mucosal soft tissue thickness and keratinised mucosa width after soft tissue grafting around dental implants. An electronic literature search was conducted of the MEDLINE database published between 2009 and 2014. Sequential screenings at the title, abstract, and full-text levels were performed. Clinical human studies in the English language that had reported changes in soft tissue thickness or keratinised mucosa width after soft tissue grafting at implant placement or around a present implant at 6-month follow-up or longer were included. The search resulted in fourteen articles meeting the inclusion criteria: Six of them reported connective tissue grafting around present dental implants, compared to eight at the time of implant placement. Better long-term soft tissue thickness outcomes were reported for soft tissue augmentation around dental implants (0.8-1.4 mm), compared with augmentation at implant

placement (-0.25-1.43 mm). Both techniques were effective in increasing keratinised tissue width: at implant placement (2.5 mm) or around present dental implants (2.33-2.57 mm). The present systematic review discovered that connective tissue grafts enhanced keratinised mucosa width and soft tissue thickness for an observation period of up to 48 months. However, some shrinkage may occur, resulting in decreases in soft tissue, mostly for the first three months. Further investigations using accurate evaluation methods need to be done to evaluate the appropriate time for grafting.

© 2015 John Wiley & Sons A/S. Published by John Wiley & Sons Ltd.

Randomized Controlled Trial Comparing the Effects of 2 Analgesic Drug Protocols in Patients who Received 5 Dental Implants.

Author(s): Meta, Isaac Fernando; Bermolen, Miriam; Macchi, Ricardo; Aguilar, Jorge

Source: Implant dentistry; Jan 2017

Publication Type(s): Journal Article

Abstract: This randomized controlled trial compares postoperative pain and swelling after placing dental implants in patients treated with nonsteroidal anti-inflammatory drugs (NSAIDs) versus NSAIDs and corticosteroids. Thirty patients received 5 dental implants each in the interforaminal region of the mandible. All patients were treated with ketorolac tromethamine 10 mg, 2 tablets daily for 2 days and amoxicillin 500 mg, 3 tablets daily for 7 days starting 24 hours before surgery. Experimental patients received an injection of betamethasone 2 mL within 10 hours after surgery. Pain perception, intraoral inflammation (InIn), and extraoral inflammation (ExIn) data were collected 3, 7, and 14 days after surgery. Patients filled out a pain visual analog scale. InIn and ExIn were recorded by observing the existence of 7 signs. One patient was excluded from control group. Pain perception, InIn, and ExIn were not different between groups at each time point. However, these variables were different from the previous time point within each group. This study suggests that there is no difference in managing postoperative pain and swelling with betamethasone versus betamethasone and ketorolac.

Marginal bone loss around dental implants with and without microthreads in the neck: A systematic review and meta-analysis.

Author(s): Niu, Wenzhi; Wang, Penglai; Zhu, Shaoyue; Liu, Zongxiang; Ji, Ping

Source: The Journal of prosthetic dentistry; Jan 2017; vol. 117 (no. 1); p. 34-40

Publication Type(s): Journal Article Review

Abstract: Whether microthreads in the crestal portion can reduce the amount of marginal bone loss (MBL) around implants has not yet been determined. The purpose of this systematic review was to investigate the marginal bone loss around dental implants with and without microthreads in the neck. This review was based on the PRISMA guidelines. An electronic search with no restrictions on language was performed from inception to August 19, 2015, in PubMed, Cochrane Central Register of Controlled Trials, EMBASE, Web of Sciences, and AMED (Ovid) databases. A manual search was also performed. Randomized clinical trials (RCTs) that compared the MBL between implants with and without microthreads in the neck were included. Qualitative synthesis and meta-analysis were performed. MBL was measured by using the mean difference (MD). Review Manager v5.3 software was used for meta-analysis ($\alpha=.05$). Five articles were included in the qualitative synthesis, and 3 articles were included in the meta-analysis. Four studies found that a microthread design can significantly reduce MBL under functional loading, whereas 1 study found no significant difference. The homogeneity test of meta-analysis confirmed acceptable heterogeneity among the 3 studies ($I^2=0.49$). A random-effects model was used. The result shows that MBL around implants

with microthread design can be reduced significantly ($P=.030$; MD: -0.09; CI: -0.18 to -0.01). Meta-analysis showed that microthread design in the implant neck can reduce the amount of MBL; however, RCTs included in the review were few and the difference was small. In clinical practice, an implant with a roughened surface and microthreaded neck could be selected to maintain bone level. Copyright © 2016 Editorial Council for the Journal of Prosthetic Dentistry. Published by Elsevier Inc. All rights reserved.

Database: Medline

Journal Tables of Contents

Click on the hyperlinked journal title (+Ctrl) for the most recent tables of contents.

If you would like any of the papers in full text then please email the library:

library@uhbristol.nhs.uk

[British Dental Journal](#)

January 2017, Volume 222, Issue 1

[Evidence Based Dentistry](#)

Volume 17, Issue 4

[International Journal of Oral and Maxillofacial Implants](#)

Jan/Feb 2017, Volume 32, Issue 1

[International Journal of Prosthodontics](#)

Jan/Feb 2017, Volume 30 , Issue 1

[Journal of Clinical Periodontology](#)

January 2017, Volume 44, Issue 1

Exercise: Outcome Reliability

Inter-rater reliability	Intra-rater reliability	Test retest reliability
Looks at the level of agreement between assessments by <i>one rater</i> of the same material at two or more different times.	Refers to the level of agreement between the initial test results and the results of repeated measurements made at a later date.	This measures the level of agreement between assessments made by <i>two or more raters</i> at the same time.

Librarians on demand!

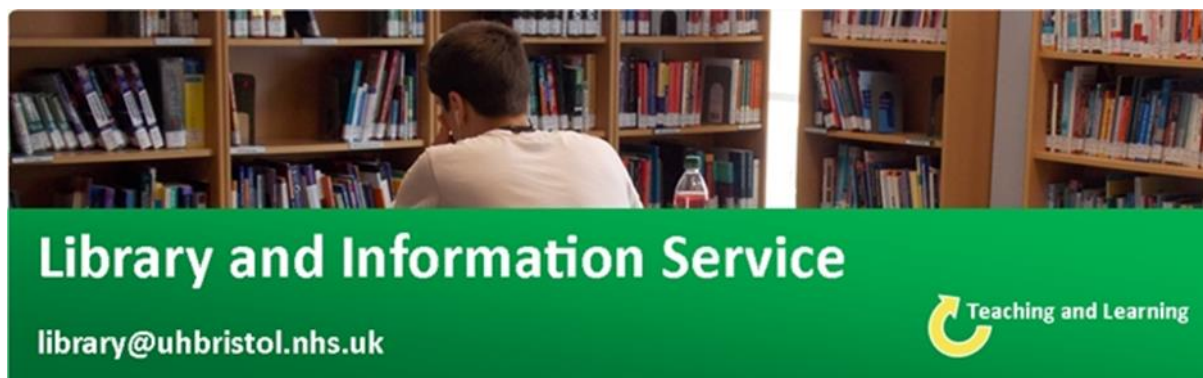
Do you urgently need to find evidence to support your treatment of a patient? Would you like immediate information about a particular therapy, practice, condition, or other clinical need?

The Library can provide swift assistance with a range of our services, including literature searches and access to full text articles.

You can discuss your **urgent literature search** needs with a librarian immediately by calling [extension 20105](tel:20105). A librarian can also be with you in your clinical area usually within 15 minutes.

For **speedy article requests** and other library services, email library@uhbristol.nhs.uk. If you specify your urgent need, we will prioritise this.





Library Opening Times

Staffed hours: 8am-5pm, Mon-Fri

Swipe-card access: 7am-11pm, 7 days a week

**Level 5, Education and Research Centre
University Hospitals Bristol**

Contact your Outreach Librarian:

Jo Hooper

library@uhbristol.nhs.uk

Ext. 20105